

# 18

## Arthrodeses of the First Metatarsophalangeal Joint

DOMENICK A. CALISE  
PRAYA MAM  
VINCENT J. HETHERINGTON

A versatile procedure in the armamentarium of the foot surgeon is arthrodesis of the first metatarsophalangeal joint. Considering the large number of indications for metatarsophalangeal joint fusion, there are relatively few contraindications. Since Glutton<sup>1</sup> first described fusion of the first metatarsophalangeal joint, there have been numerous modifications and alterations to the procedure. Advances in fixation technique and in biomechanics have allowed for improved methods of fusion and greater ease of performance. This chapter discusses indications and contraindications for fusion of the first metatarsophalangeal joint. Technical considerations such as surgical approach, position of fusion fixation techniques, and postoperative care are also discussed.

### PREOPERATIVE CONSIDERATIONS

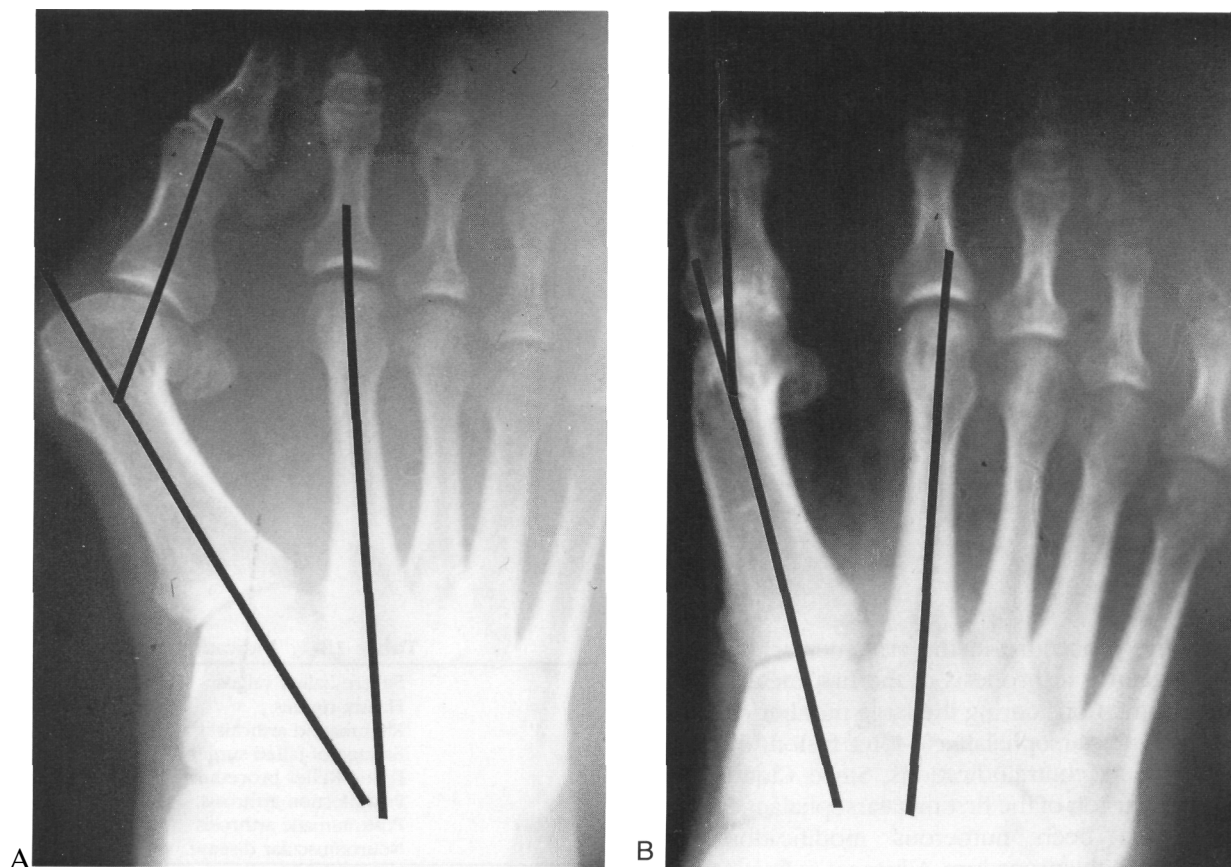
The versatility of first metatarsophalangeal joint (MPJ) fusion is evident in the number of indications that exist for this procedure (Table 18-1). The most commonly cited indications for fusion are hallux valgus and hallux rigidus.<sup>2-11</sup> Other indications include rheumatoid arthritis,<sup>12-18</sup> salvage of failed hallux valgus surgery (including failed Keller procedures),<sup>5,8-10,18-21</sup> posttraumatic arthrosis,<sup>8-11</sup> postosteomyelitis, and sep-

**Table 18-1. Indications**

- Severe hallux valgus
- Hallux rigidus
- Rheumatoid arthritis
- Salvage of failed surgery
- Failed Keller procedure
- Postinfection arthrosis
- Posttraumatic arthrosis
- Neuromuscular disease

tic arthrosis<sup>10</sup> (Fig. 18-1). Stroh and Yee presented the use of first MPJ fusion in cases in which both hallucal sesamoids were fractured and there was a failure of conservative care.<sup>22</sup> First MPJ fusion is the procedure of choice in cerebral palsy patients and others with a hallux valgus deformity from neuromuscular disorders.<sup>8,23-25</sup>

There are relatively few contraindications to MPJ fusion (Table 18-2). The most commonly cited contraindication is preexisting arthrosis of the interphalangeal joint of the hallux.<sup>5-7,11</sup> One must take special precautions preoperatively to inform the patient that there will be no motion present at the great toe and that changes in footwear will be necessary. Because osteoporotic bone may cause difficulty with placement of fixation devices, alternative procedures may be of more benefit to the patient.



**Fig. 18-1.** Preoperative and postoperative radiographs demonstrating various indications for first MPJ fusion. (A & B) Severe hallux valgus. Fig. A: preoperative radiograph; Fig. B: radiograph taken years postoperatively. (Figure continues.)

Preoperative evaluation should include a careful radiographic review including anteroposterior (AP), lateral, and oblique views to ensure competence of the hallux interphalangeal joint. It may be of benefit to construct templates of the planned resection to obtain precise joint resections and optimal alignment. Ginsburg suggests obtaining a lateral radiograph of the foot with the patient wearing a shoe normally used so that the optimal sagittal plane position of the fusion could be determined.<sup>8</sup>

The question of intermetatarsal angle relationships in first MPJ fusion has been raised by Mann and

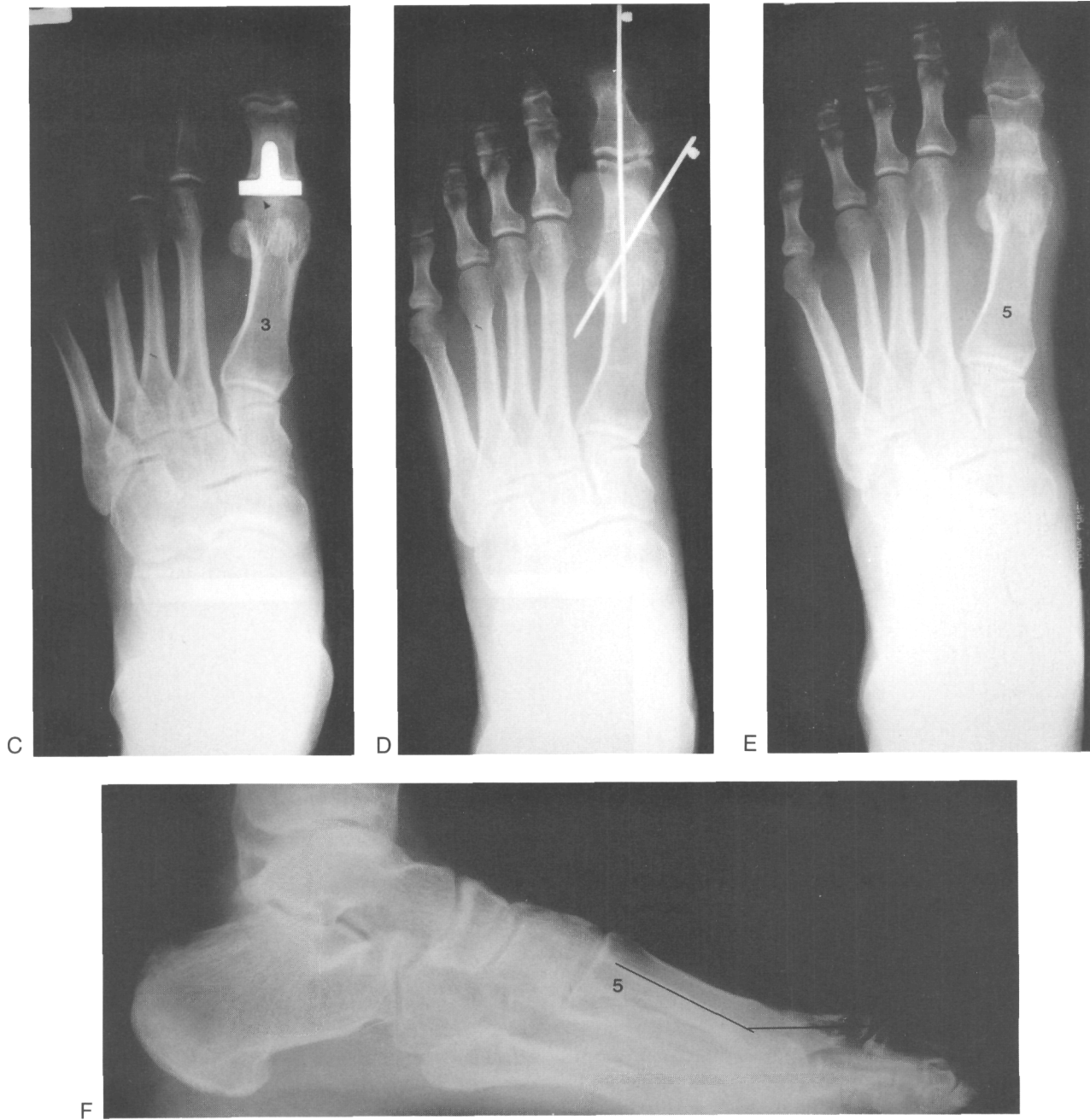others.<sup>4,10,26-29</sup> The need for ancillary first metatarsal osteotomy has been presented by relatively few authors.<sup>28-31</sup> It has been noted that the stability of the fusion in addition to the effect of the adductor complex will help to decrease the intermetatarsal angle by approximately 4° to 6°.<sup>4,10,26,27</sup> Mann states that the

**Table 18-2.** Contraindications

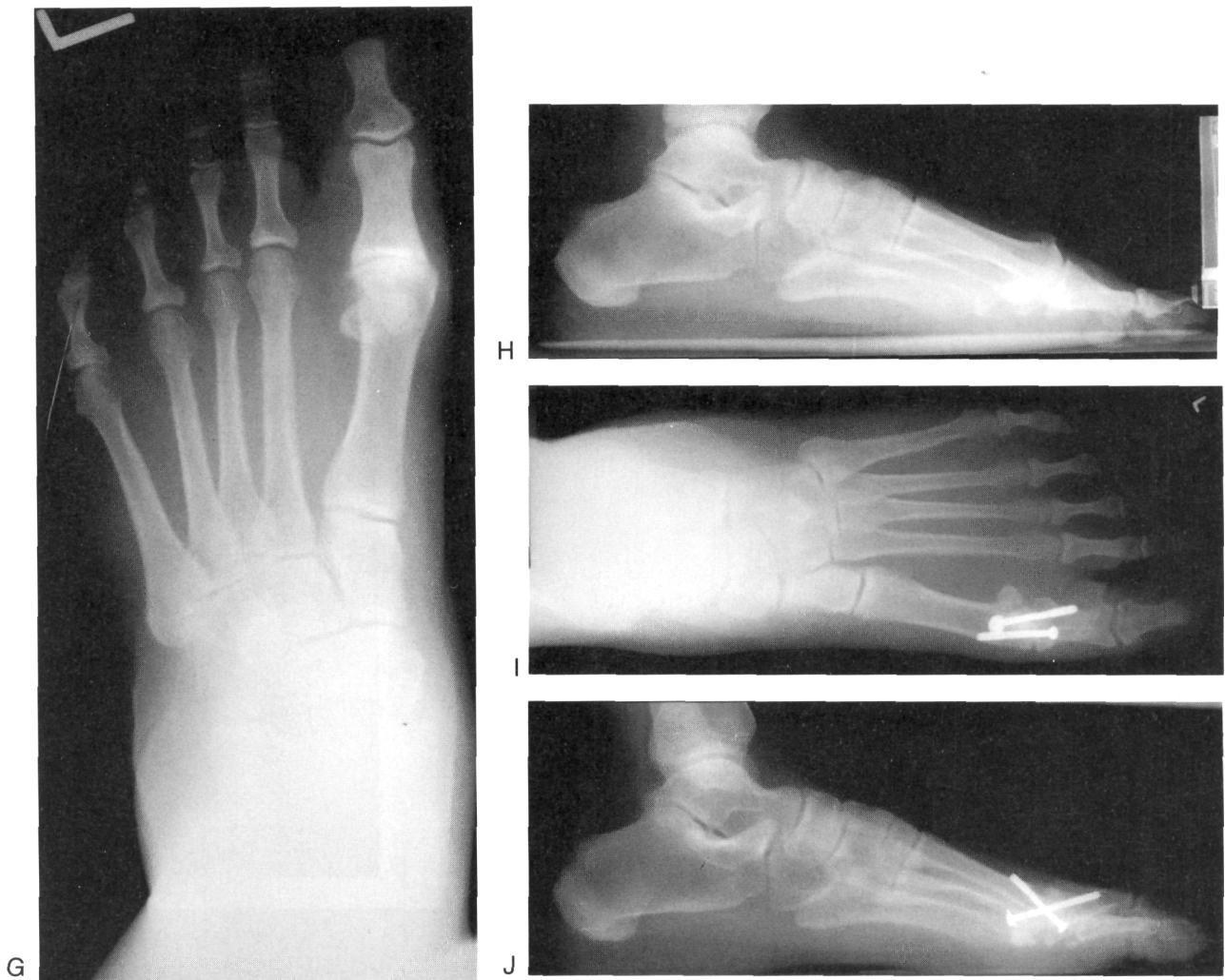---

Interphalangeal joint arthritis
Osteoporotic bone
Active infection
Noncompliance with shoe wear (high heels)

---



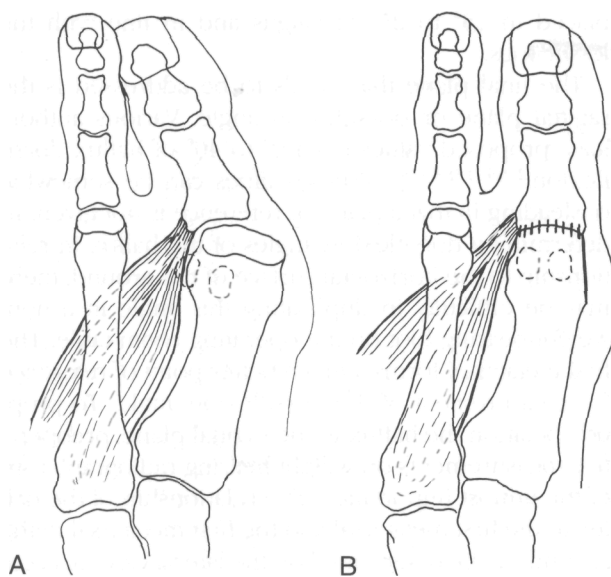
**Fig. 18-1.** (Continued). (C-F) Salvage of failed implant. Fig. C: preoperative radiograph of a painful first metatarsophalangeal joint postimplant arthroplasty; Fig. D: postoperative radiograph showing K-wire fixation; Figs. E and F: other postoperative views. (Figure continues)



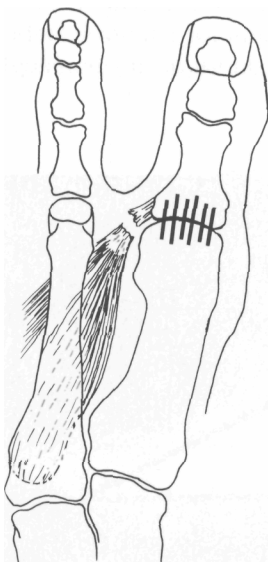
**Fig. 18-1.** (Continued). (G—J) Hallux rigidus. Fig. G: preoperative view; Fig. H: preoperative lateral view (note dorsal flag sign); Figs. I and J: postoperative views.

change in the intermetatarsal angle is directly proportional to the preoperative intermetatarsal angle and that concomitant first metatarsal osteotomy is not indicated.<sup>26</sup> Once the hallux is rigidly fused to the metatarsal, the adductor hallucis tendon and lateral soft tissue structures are no longer a deforming force. In fact, the adductor tendon gains mechanical advantage in this situation, and can now function to pull both the meta-

tarsal and the proximal phalanx toward the midline of the foot, which decreases the intermetatarsal angle<sup>4</sup> (Fig. 18-2). Interspace soft tissue dissection is discouraged in this procedure because release of the adductor tendon may lead to increased metatarsal splaying postoperatively. Postoperative splaying of the first metatarsal with a fused MPJ will lead to a hallux varus (Fig. 18-3).



**Fig. 18-2.** Decrease in intermetatarsal angle. (A & B) Schematic diagram of role of adductor hallucis in intermetatarsal angle reduction with first MPJ fusion.



**Fig. 18-3.** Diagram of hallux varus as result of extensive dissection of first intermetatarsal space. Note loss of stabilization with transection of adductor tendon.

## FUSION POSITION

The most critical aspect of MPJ fusion is the position of fusion. This key component of the procedure has been a point of great discussion since the inception of MPJ fusion. Although there is today a general consensus of opinion regarding toe position, there have been no randomized, controlled, prospective studies comparing one fusion position to another. Further, there is a paucity of research into the optimal length pattern of the first metatarsal in MPJ fusion. Although Duckworth has supplied research using pedobarographic measurements comparing gait in arthroplasty versus arthrodesis of the first MPJ, there is no statistical comparison of various fusion positions and no mention of metatarsal length patterns.<sup>32-34</sup> These pedobarographic comparisons of first MPJ arthroplasty versus fusion have shown that fusion is more stable than arthroplasty.

Perhaps one of the greatest factors concerning disagreement over fusion position is the question of reference point. Many authors supply varying degrees of valgus and toe dorsiflexion; however, no proper reference point for the particular angle has been given. When discussing the dorsiflexion angle, it is necessary to state whether this measure is taken in relationship to the ground and the hallux or to the metatarsal and the hallux. Further clouding the picture are the questions of metatarsal angulation to the ground and of heel height differences worn by men and women.

For MPJ fusion, we must consider rotation of the hallux in the frontal plane, valgus angulation of the hallux in the transverse plane (more appropriately termed *abduction angle*), and dorsiflexion of the hallux in the sagittal plane (Table 25-3).

Most authors agree that there should be no frontal plane rotation of the hallux.<sup>2-5,9,11,18,30</sup> Rotation of the hallux will result in undue pressure along either nail border, keratosis along a prominent medial or lateral condyle, or increased weight-bearing stress through the interphalangeal joint. Intraoperatively, the surgeon should use the nail plate as a guide to the degree of rotation present at the hallux.

Positioning of the hallux in the transverse plane (valgus angulation) should be such that the hallux appears to sit in natural alignment with the lesser toes. The patient should be made aware preoperatively that the great toe will not be "straight." An excessively rec-

**Table 18-3.** Fusion Position Summary

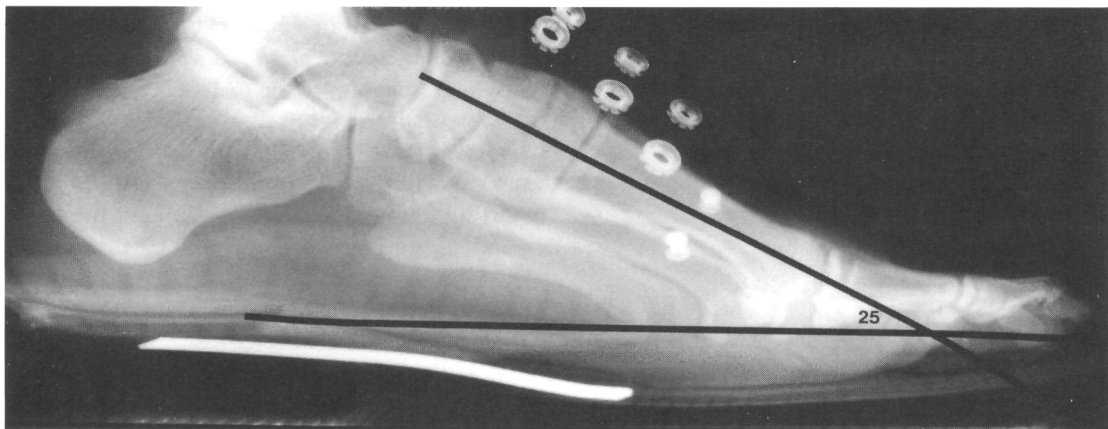
Sagittal	10°-15°	Dorsiflexion
Transverse	15°-25°	Abduction
Frontal	0°	Rotation

tus transverse plane alignment could cause problems with shoe fit and increased stress across the interphalangeal joint. Care should be taken when determining valgus position so as to not cause impingement between the first and second toe, which could lead to painful interdigital corn formation. General consensus regarding valgus angulation of the hallux has yet to be determined; from 5° to 30° of valgus have been proposed as a suitable transverse plane angulation.<sup>2,7,9-11,16,18,20,30</sup> Fitzgerald, in a long-term follow-up study, noted that in cases in which the MPJ was fused in less than 20° of valgus the incidence of postoperative degenerative changes at the interphalangeal joint of the hallux was three times greater than those fused in excess of 20° of valgus.<sup>6</sup> Smith noted that rheumatoid patients could tolerate a greater degree of valgus because of the laterally deviated position of the lesser toes with less possibility of the first and second toes impinging on each other. Smith went on to recommend that rheumatoid patients could be fused in 25° to 30° of valgus.<sup>18</sup> In general, the hallux should be

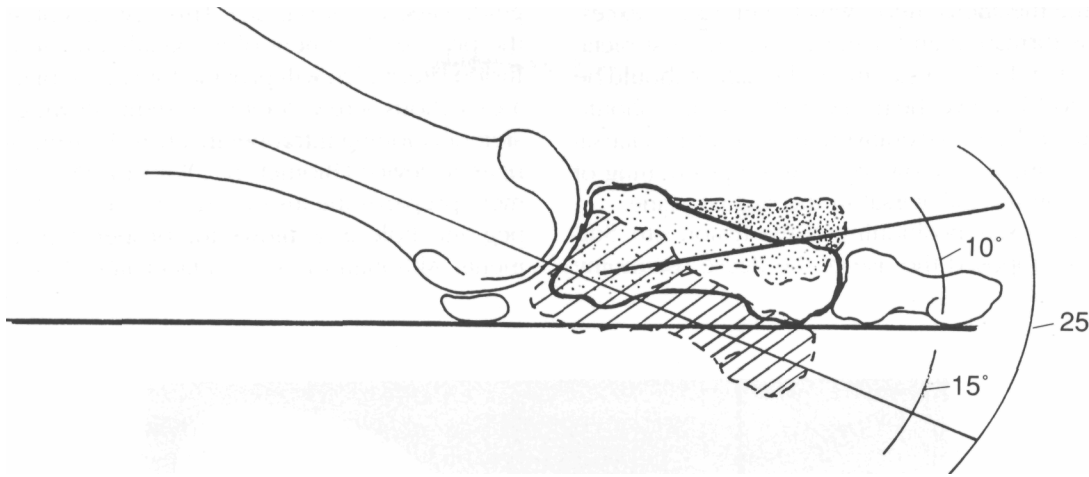
placed in 15° to 25° of valgus and in line with the lesser toes.

The final plane that needs to be addressed is the sagittal plane or dorsiflexion angle. Various authors have proposed values from 0° to 40° of hallux dorsiflexion.<sup>2-5,9,11,18,30,35,37</sup> These values can be somewhat misleading in that a plane of reference is not given. In determining dorsiflexion angles of the hallux in relationship to the horizontal surface of the ground, there may be difficulty in duplicating this angle in a non-weight-bearing foot on the operating room table. The first metatarsal forms a much better point of reference for measurement of the dorsiflexion angle. To properly position the hallux in the sagittal plane, preoperative measurements on weight-bearing radiographs are of the utmost importance. The relationship of the hallux to the first metatarsal and the first metatarsal to the ground can be determined on the lateral view. According to Ginsburg, an extra measure of accuracy can be achieved by obtaining a lateral weight-bearing radiograph while the patient is wearing a shoe with the preferred heel height<sup>8</sup> (Fig. 18-4).

The first metatarsal is usually angulated 15° to the ground (first metatarsal declination angle), which would translate to the hallux being angled 15° to the first metatarsal on stance. Most authors agree that 10° of dorsiflexion of the hallux above the horizontal plane is sufficient for pain-free ambulation.<sup>9,18,30</sup> If the usual first metatarsal declination angle of 15° is added




**Fig. 18-4.** Preoperative lateral radiograph with patient wearing a shoe. Note first metatarsal declination angle that will be the frame of reference for determining the sagittal plane position of fusion intraoperatively,



**Fig. 18-5.** Determination of hallux sagittal plane positioning; 10°, hallux dorsiflexion angle; 15°, preoperatively measured first metatarsal declination angle; 25°, angle of fusion between hallux and metatarsal. The hallux dorsiflexion angle should not exceed 15°.

to the recommended 10° of dorsiflexion above the horizontal, a hallux to first metatarsal dorsiflexion angle of 25° results (Fig. 18-5). This angle can easily be measured intraoperatively with a sterile goniometer (Fig. 18-6). A great toe that is fused in less than 10° of dorsiflexion above the horizontal will subject the pa-

tient to pain at the distal tip of the toe and increase stress at the interphalangeal joint of the hallux. Insufficient dorsiflexion will also lead to excess callus formation at the plantar aspect of the hallucal interphalangeal joint. Dorsiflexion angles greater than 15° above the horizontal will cause excessive retrograde pres-

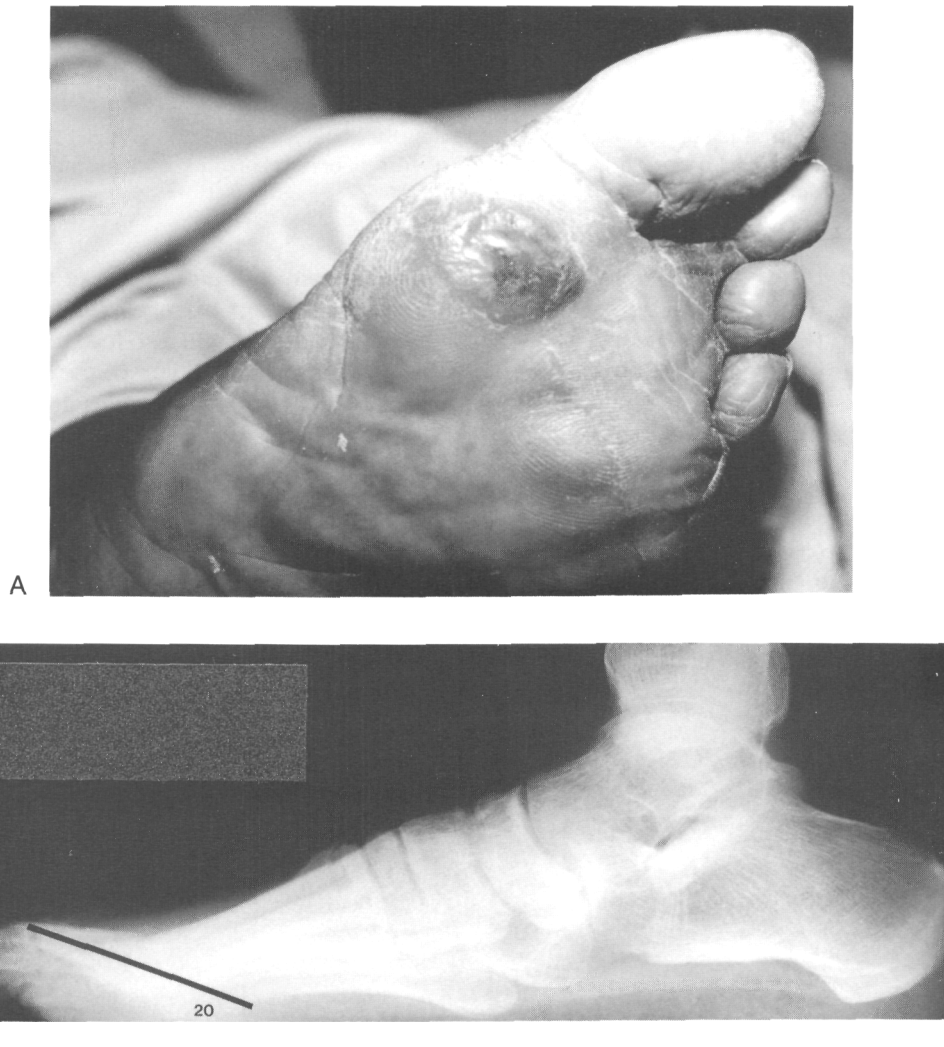


**Fig. 18-6.** Goniometer used intraoperatively to ensure precise position of first MPJ fusion.

sure on the metatarsal head, which will lead to excessive callus formation and pain beneath the first metatarsal<sup>2,6,10</sup> (Fig. 18-7). In summary, the hallux should be fused 10° to 15° above the horizontal; this value should be added to the preoperatively measured metatarsal declination angle to allow for accurate positioning of the hallux on the metatarsal in the sagittal plane.

To ensure exact positioning of the fusion site, Sullivan<sup>38</sup> has proposed the use of the Reese osteotomy

guide (Reese, Peoria, AZ). This instrument allows for the precise placement of a sagittally directed chevron fusion site, which will provide for simple placement of a cancellous screw. Another system allowing exact fusion positioning intraoperatively is the truncated cone reamer device (Biomet Inc., Warsaw, IN). This instrument prepares the fusion site into a perfectly matched peg and hole and allows for proper angular adjustments. Although the system facilitates placement, it is



**Fig. 18-7.** Complication of improper sagittal plane positioning of fusion site. (A) Sub-first metatarsal tylosis. Note preulcerative appearance of lesion. (B) Lateral radiograph of same foot shows excessive dorsiflexion of hallux on first metatarsal.



rather cumbersome in its use, and the instrumentation involved is somewhat complex. Improper use of the truncated cone reamer can lead to severe soft tissue damage.

## FIXATION METHODS

Many different methods of fixation for first MPJ fusion have been proposed.<sup>2,4,7-9,18,30,39-44</sup> McKeever<sup>2</sup> presented the use of screw fixation via a plantarly placed screw running from distal to proximal. Harrison and Harvey<sup>4</sup> proposed the use of a Charnley clamp for fixation. The fixator was left in place for 3 weeks then replaced with a walking cast that completely incorporated the hallux. The cast was left in place for an additional 3 weeks. There have been no other reports to support or refute the use of external fixation devices for first MPJ fusions. Salis-Sogliio has discussed the use of the dynamic compression plate applied to the dorsum of the first MPJ for fixation of the fusion site<sup>7</sup>. They made no comment regarding the advantages of this form of fixation.

The use of K-wires and Steinman pins for fixation of MPJ fusion has been supported by many authors.<sup>8,9,18,20,40</sup> The advantages to pin fixation include ease of the procedure, ability to provide stability in porotic bone, and ability to manipulate the fusion site if minor angular changes are necessary. Disadvantages include the possibility of pin tract infection and lack of compression. Wilson has presented the use of the Rush pin as a method of fixating MPJ fusions.<sup>39</sup> The intramedullary Rush nail supplies considerable compressive force across the fusion site, a factor that Wilson states "allows for rapid arthrodesis." Various other methods of fixation have been presented including the use of Herbert screws, wire loop, suture, and combinations of wire and pins.<sup>40-44</sup> The use of cannulated screws is an excellent method of first MPJ fusion which, to our knowledge, has yet to be presented in the literature.

Sykes performed an elaborate biomechanical study using cadaveric specimens to determine the stability of various fixation devices used in first MPJ fusions.<sup>43</sup> He compared cancellous screws used with dome arthrodesis and planar arthrodesis with planar surfaces held by Charnley clamps and various wire constructs. The use of K-wires, Stienman pins, or plate fixation was not investigated. The study concluded that

the best method of fixation was the use of planar surface fusion with a 4.0 cancellous screw; the method of fusion that was second in resistance to load was screw fixation with domed fusion surfaces. The study also noted that the critical component in screw fixation was an intact plantar flange on the proximal phalanx base. Screws were placed from plantar medial distal to dorsal lateral proximal. The head of the screw must impact against the intact plantar flange to obtain sufficient compression across the fusion site.

## SURGICAL PROCEDURE

The surgical approach to the first MPJ is relatively straightforward, consisting of either a dorsomedial or a medial incision. The incision starts at about midshaft on the first metatarsal and extends out to the distal aspect of the proximal phalanx. Dissection is kept to a minimum because there is no need for interspace procedures or sesamoid rotation. The incision is carried down to the level of the first MPJ capsule where a linear capsulotomy is performed in line with the skin incision. The extensor hallucis longus tendon is reflected laterally, and the MPJ is disarticulated. Resection of the medial eminence is performed as needed, taking care to avoid excessive bone removal. At this point one must decide on what type of fusion is to be performed; options include end-to-end flat surface fusion, peg-in-hole fusion, or simple cartilage resection.<sup>2,3,5,7,8,11,30,31,35,36</sup> Each option has its advantages and disadvantages, but the final aim is the same; with any method used, there should be good bone-to-bone contact with no cartilaginous or soft tissue interposition.

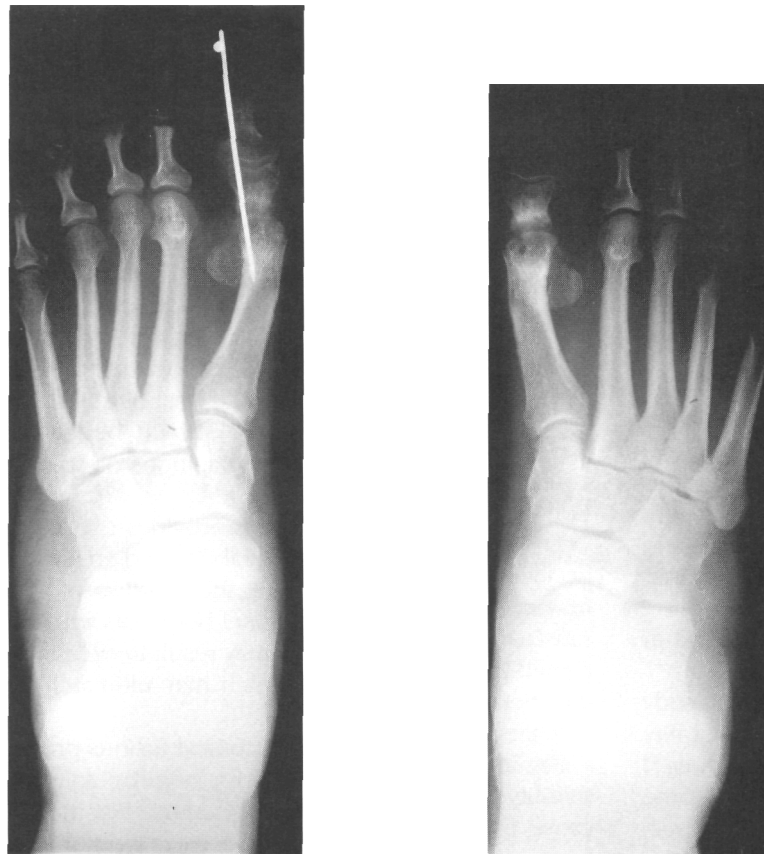End-to-end fusion provides excellent bone apposition for increased stability and greater surface area for fusion. However, if the position of the hallux is not satisfactory, revisional bone cuts will be necessary. Repeated bone cuts may result in excessive shortening of the metatarsal, which may ultimately result in lesser metatarsalgia.

Peg-in-hole and conical fusions provide remarkable stability and allow for angular adjustments but may cause excessive shortening. Peg-in-hole and conical fusions also require greater wound manipulation, are technically more demanding, and may require the use of specialized instrumentation such as power reamers.

Simple cartilage removal allows for minimal loss of bone and provides for a high degree of angular adjustment from the ball-and-socket architecture of the first MPJ. However, this ability to easily adjust position also renders simple cartilage resection highly unstable. Another shortcoming of simple cartilage resection is that the subchondral bone is relatively dense, a factor that may delay union. To overcome this problem, it is necessary to drill multiple holes in the subchondral surface of the metatarsal head and phalangeal base. These holes will increase the surface area for fusion and allow for vascular bridging and bone formation at the site. This is easily accomplished by using a 1.5-mm drill bit.

Another method of increasing surface area for ingrowth is the "fish-scale" technique. Using a small sharp osteotome, multiple small cuts are made in the subchondral surface on both sides of the joint. These cuts should penetrate only through the subchondral bone, and care should be taken not to create fractures that propagate up the shaft of either the metatarsal or proximal phalanx.

When the surfaces of the metatarsal head and base of the proximal phalanx are prepared, the next step in the procedure is the mating of the two surfaces and a check of angular relationships. This step is facilitated by the use of a goniometer or intraoperative radiographs. Once the position of fusion is deemed accept-



**Fig. 18-8.** (A-B) Radiographs demonstrating nonunion of first MPJ fusion.

able, a method of fixation is selected. Recommended fixation techniques include screws, plates, and K-wires. On completion of fixation, intraoperative radiographs are obtained as necessary and closure is performed in the usual fashion. One should keep in mind the words of Fitzgerald: "the precise operative technique is not important provided it maintains the position obtained at operation until the arthrodesis is sound."<sup>6</sup> The patient is then placed in a non-weight-bearing cast for approximately 6 to 8 weeks.

## COMPLICATIONS

Complications associated with first MPJ fusion are relatively few in number. Wound complications involving dehiscence, postoperative infections, and prolonged edema present at a rate similar to any other podiatric procedure and are not a major concern. Improper positioning of the fusion is a serious complication that can be avoided by proper preoperative planning and intraoperative decision making. Fusions that have been improperly positioned present with various signs and symptoms including inability to fit into shoes, interdigital heloma, incurvated or painful nails, lesser metatarsalgia, sub-first metatarsal pain, and tylooma formation. One of the more significant complications associated with malpositioning of the fusion is plantar ulceration at the first metatarsal head. This is particularly true in cases in which a fusion has been performed for a rheumatoid first MPJ. Thin plantar skin with the loss of the plantar fat pad in rheumatoid patients puts these patients at risk for developing plantar ulceration with an error in sagittal plane positioning of the fusion.

Another possible complication of MPJ fusion is that of nonunion (Fig. 18-8). Nonunion rates have been noted to range from 2 to 23 percent with an average of 10 percent.<sup>4,5,9-11,16,18,30,45</sup> In most cases, the non-union develops into a painless pseudoarthrosis and no further intervention is needed. Possible causes for nonunion include hardware failure, improper or no fixation, and steroid or methotrexate use in rheumatoid patients. Patients occasionally will have problems with painful internal fixation devices, most often noted in plantar placed screws.

A final complication to consider is that of interphalangeal joint arthrosis. This complication can be

avoided by ensuring proper transverse and sagittal plane positioning intraoperatively, thereby relieving abduction and dorsiflexion forces on the interphalangeal joint.

## REFERENCES

1. Glutton HH: The treatment of hallux valgus. *St. Thomas Rep* 22:1, 1984
2. McKeever D: Arthrodesis of the first metatarsophalangeal joint for hallux rigidus and metatarsus primus varus. *J Bone Joint Surg* 34:129, 1952
3. Marin G: Arthrodesis of the first metatarsophalangeal joint for hallux valgus and hallux rigidus. *Guy's Hosp Rep* 109:174, 1960
4. Harrison MHM, Harvey FJ: Arthrodesis of the first metatarsophalangeal joint for hallux valgus and rigidus. *J Bone J Surg*, 45A:471, 1963
5. Marin G: Arthrodesis of the first metatarsophalangeal joint for hallux valgus and hallux rigidus: a new method. *Int Surg* 50:175, 1968
6. Fitzgerald JAW: A review of long term results of arthrodesis of the first metatarsophalangeal joint. *J Bone Joint Surg* 51B:488, 1968
7. Salis-Soglio G, Thomas W: Arthrodesis of the metatarsophalangeal joint of the great toe. *Arch Orthop Trauma Surg* 95:7, 1979
8. Ginsburg AI: Arthrodesis of the first metatarsophalangeal joint. *J Am Podiatry Assoc* 69:367, 1979
9. Mann RA, Gates JC: Arthrodesis of the first metatarsophalangeal joint. *Foot Ankle* 1:159, 1980
10. Riggs SA, Johnson EW: McKeever arthrodesis for the painful hallux. *Foot Ankle* 3:248, 1983
11. Johansson JE, Barrington TW: Cone arthrodesis of the first metatarsophalangeal joint. *Foot Ankle* 4:244, 1984
12. Leavitt DC: Surgical treatment of arthritic feet. *Northwest Med* 55:1086, 1956
13. Du Vreil HL: *Surgery of the foot*. 2nd Ed. CV Mosby, St. Louis, 1965
14. Morrison P: Complications of forefoot operations in rheumatoid arthritis. *Proc R Soc Med* 67:110, 1974
15. Watson MS: A long term follow-up of forefoot arthroplasty. *J Bone Joint Surg* 56B:527, 1974
16. Mann RA, Thompson FM: Arthrodesis of the first metatarsophalangeal joint for hallux valgus in rheumatoid arthritis. *J Bone Joint Surg* 66A:687, 1984
17. Geppert MJ, Sobel M, Bohn WO: Foot fellows review: the rheumatoid foot; part I, forefoot. *Foot Ankle* 13:550, 1992

18. Smith RW, Joanis TL, Maxwell PD: Great toe metatarsophalangeal joint arthrodesis: a user friendly technique. *Foot Ankle* 13:367, 1992
19. Henry APJ, Waugh W: The use of footprints in assessing the results of operations for hallux valgus. A comparison of Keller's operation and arthrodesis. *J Bone J Surg* 57(B):478, 1975
20. Coughlin MJ, Mann RA: Arthrodesis of the first metatarsophalangeal joint as a salvage for the failed Keller procedure. *J Bone Joint Surg* 69(A):68, 1987
21. Thompson FM: Complications of hallux valgus surgery and salvage. *Orthopedics* 13:1059, 1990
22. Stroh KI, Altman MI, Yee DY: First metatarsophalangeal joint arthrodesis: treatment for sesamoid fractures. *J Am Podiatr Med Assoc* 80:595, 1990
23. Thompson FR, McElvenny RT: Arthrodesis of the first metatarsophalangeal joint. *J Bone Joint Surg* 23:555, 1940
24. Renshaw T, Sirkin R, Drennan J: The management of hallux valgus in cerebral palsy. *Dev Med Child Neurol* 21:202, 1979
25. Richardson GE: The foot in adolescents and adults: hallux valgus in cerebral palsy, p. 879. In Crenshaw All (ed): *Campbell's Operative Orthopedics*, 7th Ed. CV Mosby, St. Louis, 1987
26. Mann RA, Katcherian DA: Relationship of metatarsophalangeal joint fusion on the intermetatarsal angle. *Foot Ankle* 10:8, 1989
27. Humbert JL, Bourbonniere C, Laurin CA: Metatarsophalangeal fusion for hallux valgus: indications and effects on the first metatarsal ray. *Can Med Assoc J* 120:937, 1979
28. Kampner SL: Total joint prosthetic arthroplasty of the great toe—a 12-year experience. *Foot Ankle* 4:249, 1984
29. Raymakers R, Waugh W: The treatment of metatarsalgia with hallux valgus. *J Bone Joint Surg* 53(B):684, 1971
30. Coughlin MJ: Arthrodesis of the first metatarsophalangeal joint with mini fragment plate fixation. *Orthopedics* 13:1037, 1990
31. Gould N: Surgery of the forepart of the foot in rheumatoid arthritis. *Foot Ankle* 3:173, 1982
32. Duckworth T, Betts RP, Franks CI: Foot pressure studies: normal and pathological gait analysis, p. 484. In Jahss MH (ed): *Disorders of the Foot and Ankle*. 2nd Ed. WB Saunders, Philadelphia, 1991
33. Duckworth T, Betts RP, Franks CI, Burke J: The measurement of pressures under the foot. *Foot Ankle* 3:130, 1982
34. Betts RP, Stockley I, Getty CJM: Foot pressure studies in the assessment of forefoot arthroplasty in the rheumatoid foot. *Foot Ankle* 8:315, 1988
35. Kelekian H: Hallux valgus, allied deformities of the forefoot and metatarsalgia. pp. 236-241. WB Saunders, Philadelphia, 1965
36. Zadik FR: Arthrodesis of the great toe. *Br Med J* 2:1573, 1960
37. Lipscomb PR: Arthrodesis of the first metatarsophalangeal joint for severe bunions and hallux rigidus. *Clin Orthop Relat Res* 142:48, 1979
38. Sullivan BT: Use of the Reese osteotomy guide system for fusion of the first metatarsophalangeal joint. *J Bone Joint Surg* 30:43, 1991
39. Wilson CL: A method of fusion of the metatarsophalangeal joint of the great toe. *J Bone Joint Surg* 40(A):384, 1958
40. Wilson JN: Cone arthrodesis of the first metatarsophalangeal joint. *J Bone Joint Surg* 49(B):98, 1967
41. Ghana GS, Andrew TA, Cotterill CP: A simple method of arthrodesis of the first metatarsophalangeal joint. *J Bone Joint Surg* 66(B):703, 1984
42. Phillips JE, Hooper G: A simple technique for arthrodesis of the first metatarsophalangeal joint. *J Bone Joint Surg* 62(B):774, 1986
43. Sykes A, Hughes AW: A biomechanical study using cadaveric toes to test the stability of fixation techniques employed in arthrodesis of the first metatarsophalangeal joint. *Foot Ankle* 7:18, 1986
44. Wu KK: Arthrodesis of the metatarsophalangeal joint of the great toe with Herbert screws: a clinical analysis of 27 cases. *J Foot Ankle Surg* 32:47, 1993
45. Moynihan FJ: Arthrodesis of the metatarsophalangeal joint of the great toe. *J Bone Joint Surg* 49B:544, 1967