

28

Entrapment Neuropathies

STEPHEN J. MILLER

DEFINITIONS

Peripheral neuropathy is defined as deranged function and structure of peripheral, motor, sensory, and autonomic neurons, involving either the entire neuron or selected levels.^{1,2} The major categories of peripheral neuropathies are seen in Table 28-1. Because this chapter is concerned with nerve problems seen in the foot that are most amenable to local treatment, only the last four categories are considered.

A true *neuroma* consists of an unorganized mass of ensheathed nerve fibers embedded in scar tissue that originate from the proximal end of a transected peripheral nerve.³ Neuromas are always the result of trauma. When the injury is incomplete (partial laceration, traction) or the result of blunt trauma the lesion will form within the epineurium and produce a fusiform or eccentric nodular swelling termed "neuroma-in-continuity."⁴ In either case, the axonal elements are disrupted such that they are arranged in a somewhat haphazard fashion.

Morton's neuroma, the interdigital or intermetatarsal lesion accurately described initially by the English chiropodist Louis Durlacher,⁵ is actually a misnomer. It is neither a true neuroma nor a neoplasm. Rather, it is best defined as a mechanical neuropathy with compression, stretching, and entrapment components in its etiology. Pathologically, this lesion is a progressive degenerative, and at times regenerative, process in which early and late changes may be found. Characteristic histologic findings support this etiology (Table 28-2). As a result, Morton's neuroma might be more accurately termed a perineural fibroma.^{6,7}

Mechanical peripheral neuropathies are caused by local or extrinsic compression phenomena or im-

pingement by an anatomic neighbor causing a localized entrapment.⁸ Entrapment may also be caused by scarring or fibrosis from local trauma, bleeding, or traction that tends to bind the nerve down, thus restricting normal mobility within the tissues.

Traumatic neuropathies are the result of either closed injuries or open injuries to peripheral nerves. Early treatment usually involves prophylaxis and repair, while later attention is directed toward the painful neuromas or nerve entrapments that result from the body's healing processes.

Nerve sheath tumors are named according to their structure derivation. They can be benign or malignant. Nerve sheath tumors fall under another general category known as parenchymatous disorders because they can involve excessive growth of specific neural elements: neuron or axon, Schwann cell, perineurial cell, and endoneurial fibroblast. This is in contrast to the lesions described previously, termed interstitial disorders, in which external factors cause the derangements.¹²

ANATOMY

Neuralgic pain in the foot and ankle can be traced to problems with the peripheral nerves. When the presenting symptoms—burning, tingling, numbness and other paresthesias—sound as though there is nerve involvement, it is important to exclude proximal and systemic causes of neuropathy. Examples include radiculopathy, compression syndromes, entrapment neuropathies, autonomic dysfunction, diabetes mellitus, ischemia, pernicious anemia, polycythemia vera,

Table 28-1. Peripheral Neuropathies

Vascular-ischemic
Metabolic
Nutritional
Infectious
Toxic
Hereditary
Inflammatory demyelinating
Mechanical
Compression
Entrapment
Traumatic
Closed injuries
Open injuries
Painful neuromas
Nerve sheath tumors

hypothyroidism, erythromelalgia, and alcoholism and other systemic diseases.

To further isolate problems within the nerves of the foot, a thorough understanding of the peripheral neuroanatomy and cord level innervation is essential. Six nerves cross the ankle joint into the foot: the saphenous nerve, the medial dorsal cutaneous nerve, the intermediate dorsal cutaneous nerve, the deep peroneal nerve, the posterior tibial nerve, and the lateral dorsal cutaneous nerve or sural nerve⁹ (Figs. 28-1 through 28-4).

There can be anatomic variations of all the peripheral nerves, deviating somewhat from these descriptions. However, the basic pattern must be understood and applied in the clinical setting. Also required is a thorough knowledge of the neurodermatomes (Table 28-3; Figure 28-5) and muscle innervation by peripheral nerve and spinal cord level. This battery of information is essential so that the clinician can isolate and locate peripheral nerve pathology in the foot, ankle, and leg.

Table 28-2. Histopathology of Morton's Neuroma (Perineural Fibroma)

Venous congestion (early stages)
Endoneural and neural edema (early stages).
Perineural, epineural, and endoneural fibrosis and hypertrophy (late stages)
Renaut's body formation (evidence of local pressure damage)
Hyalinization of the walls of endoneurial blood vessels.
Subintimal and perivascular fibrosis that may lead to occlusion of local blood vessels (resembling healed vasculitis)
Mucinous changes endoneurially and perineurally
Demyelination with axonal loss

Table 28-3. Motor Innervation to the Leg and Foot

Muscle	Peripheral Nerve	Spinal Level
Tibialis anterior	Deep peroneal	L _{4,5}
Extensor digitorum longus	Deep peroneal	L _{4,5}
Extensor hallucis longus	Deep peroneal	L _{4,5}
Peroneus tertius	Deep peroneal	L _{4,5}
Gastrocnemius	Tibial	S _{1,2}
Soleus	Tibial	S _{1,2}
Plantaris	Tibial	S _{1,2}
Popliteus	Tibial	L _{4,5} , S ₁
Flexor hallucis longus	Tibial	S _{2,3}
Flexor digitorum longus	Tibial	S _{2,3}
Tibialis posterior	Tibial	L _{4,5}
Peroneus longus	Superficial peroneal	L ₅ , S _{1,2}
Peroneus brevis	Superficial peroneal	L ₅ , S _{1,2}
Extensor digitorum brevis	Deep peroneal	S _{1,2}
Abductor hallucis	Medial plantar	S _{2,3}
Flexor digitorum brevis	Medial plantar	S _{2,3}
First lumbricalis	Medial plantar	S _{2,3}
Flexor hallucis brevis	Medial plantar	S _{2,3}
Abductor digiti quinti brevis	Lateral plantar	S _{2,3}
Quadratus plantae	Lateral plantar	S _{2,3}
Second, third, fourth lumbricales	Lateral plantar	S _{2,3}
Adductor hallucis	Lateral plantar	S _{2,3}
Flexor digiti quinti brevis	Lateral plantar	S _{2,3}
Plantar interossei	Lateral plantar	S _{2,3}
Dorsal interossei		
First, second	Deep peroneal, lateral plantar	S _{1,2,3}
Third, fourth	Lateral plantar	S _{2,3}

PERIPHERAL NERVE ANATOMY

A peripheral nerve is composed of many nerve fibers, which may vary in length from 0.5 mm. to 1 m or more.^{10,11} Each nerve fiber consists of the *axon*, with its thin outer layer or *axolemma* surrounding the viscous *axoplasm*, the *Schwann cell*, and *Schwann cell sheath* with or without myelin (Fig. 28-6A). Myelinated nerves have one axon per Schwann cell, while unmyelinated fibers have several axons surrounded by a single Schwann cell (Fig. 28-6B). It should be noted, as conduction rates are directly related to fiber size, that the larger myelinated fibers conduct at a more rapid rate than unmyelinated axons.

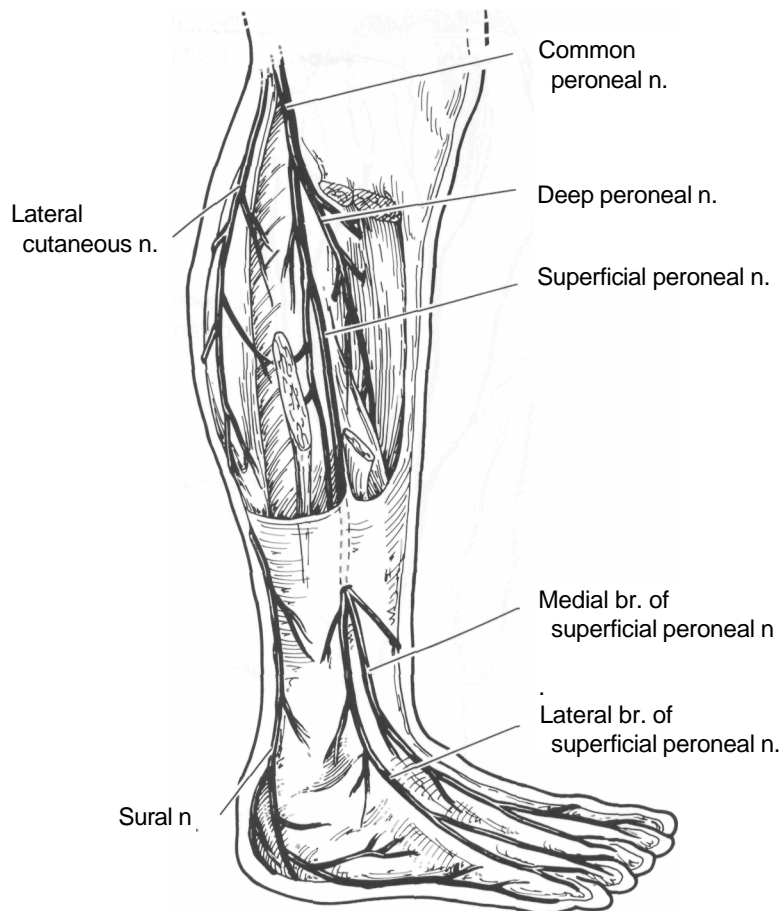


Fig. 28-1. Peripheral nerves of front and lateral side of leg and dorsum of foot.

Each nerve fiber is surrounded by an endoneurial sheath (*endoneurium*), which includes the basal membrane of the Schwann cell outside the myelin sheath as well as the reticular and collagen fibers that provide the supporting framework (Fig. 28-7).

Within a peripheral nerve is a *fascicle*, a unit consisting of a group of nerve fibers surrounded by the *perineurium*. This perineurial sheath is composed of epithelial-like cells as an inner layer and collagen connective tissue as an outer layer (Fig. 28-7).

Finally, a single fascicle or group of fascicles will make up the peripheral nerve itself. The collagenous connective support tissue surrounding these fascicles is known as the *epineurium*, which may be external or interfascicular. It is this tissue that can become bound

with local scar tissue in certain entrapment neuropathies.

DIAGNOSIS OF NERVE INJURIES AND ENTRAPMENTS

Patients afflicted with nerve injuries or compression problems tend to experience pain and paresthesia typical of nerves. Sometimes these are enhanced with bizarre symptoms, especially when the patient has an overly anxious or hysterical personality. The pain is characteristically of a sharp or burning nature, localized over the sensory distribution of the involved nerve. The extent of the area involved will depend on

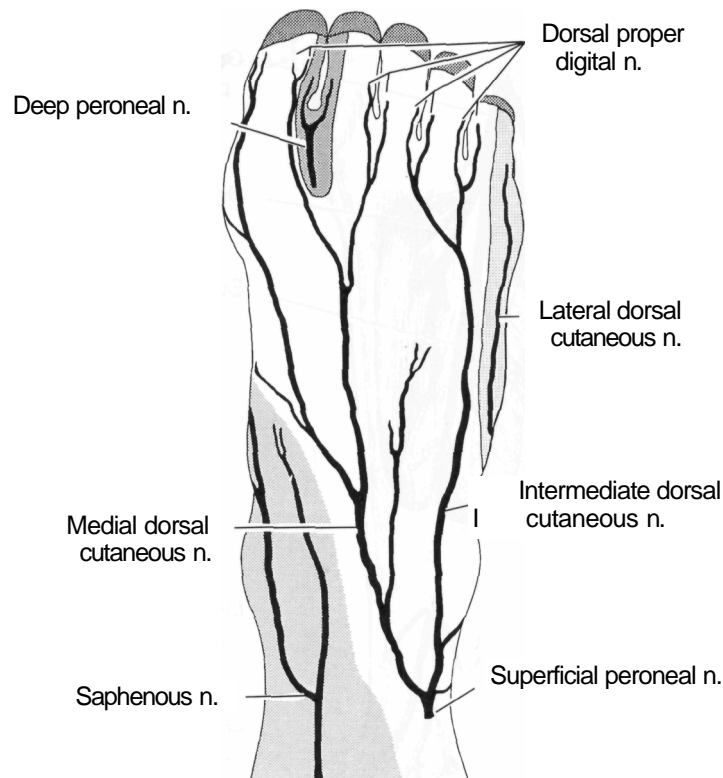


Fig. 28-2. Peripheral nerves on dorsum of foot.

what portion of the nerve trunk is damaged or impinged.

Early in the entrapment process the patient may experience muscle cramps or a feeling of tight, heavy, or swollen feet. Dysesthesia, hyperesthesia, and hypesthesia can be extremely uncomfortable. The pain may then progress to altered sensations of tingling, burning, or numbness that are often present at rest and may increase in severity at night, causing restlessness. It is aggravated by increased extremity movement and activity; proximal radiation is common. Altogether, the symptoms can be very exasperating and debilitating, to the point of causing complete disability. They may further precipitate a reflex sympathetic dystrophy syndrome.

When a motor nerve is primarily involved, the symptoms are less well defined as to distribution. Motor nerve pain is characteristically dull and aching in nature, affecting the muscle or muscles innervated by the affected nerve. Local joints will also hurt, especially

proximally. As the neuropathy persists over time, muscle tenderness can be found, leading eventually to paresis and disuse atrophy.

Sensorimotor examination is central to objective evaluation. Decreased two-point tactile discrimination greater than 6 mm is an early sign. When the nerve is accessible, deep palpation may reveal enlargement or elicit tenderness and paresthesia; often, it will reproduce the patient's symptoms. Percussion of the nerve causing distal radiation or paresthesia is a positive Tinel's sign while proximal and distal radiation indicates a positive Valleix phenomenon. Both are indicative of traumatic or compression damage.

Diagnostic nerve blocks, selectively anesthetizing the suspected nerve with lidocaine or bupivacaine, will result in dramatic relief when there is a nerve entrapment. This helps identify the nerve trunk and localize nerve branches to further isolate the problem. Perineural infiltration with steroid at the site of entrapment can also remarkably decrease symptoms by re-

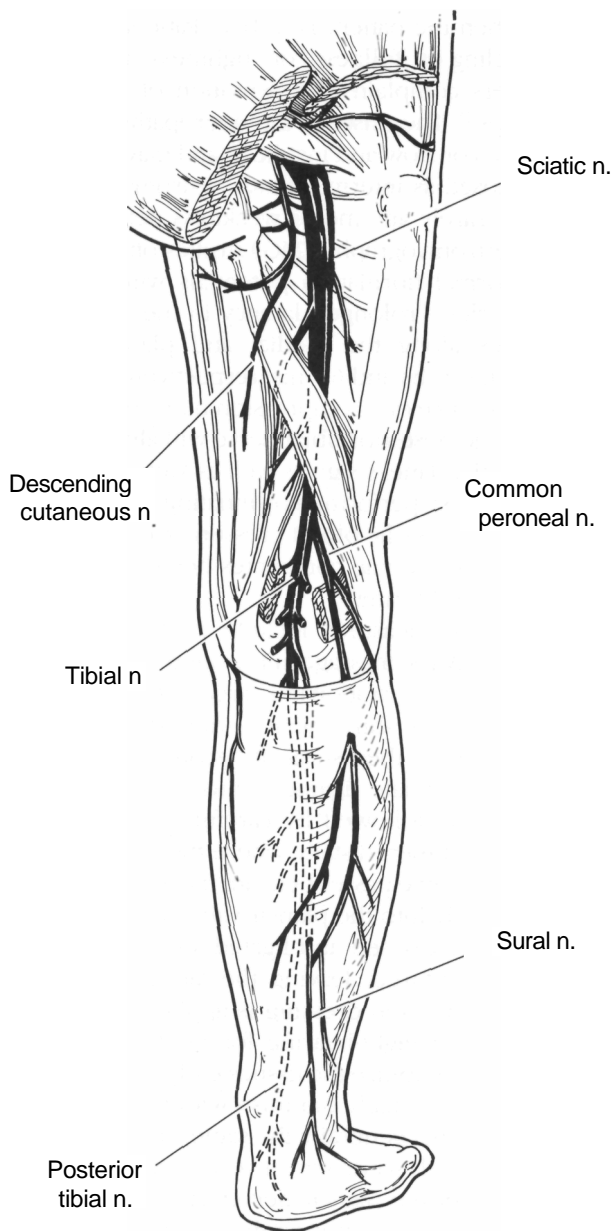


Fig. 28-3. Nerves of posterior lower limb.

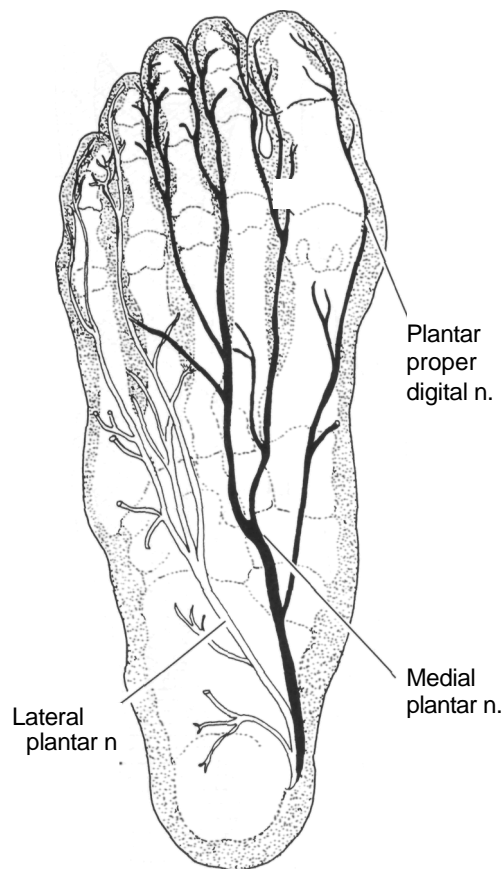


Fig. 28-4. Plantar nerves.

studies are less helpful unless there is virtually complete nerve conduction blockade.

Magnetic resonance imaging (MRI) has provided some rather striking visualizations of nerve entrapments, although diagnostic value relative to cost must be considered because it is an expensive test. It can give good contrasts in soft tissue density.

TARSAL TUNNEL SYNDROME

ducing inflammation and fibrosis, another good diagnostic aid.

Nerve conduction velocity is decreased in most cases of nerve entrapment, although normal findings do not rule out impingement. Electromyographic

The symptom complex caused by entrapment of the posterior tibial nerve was first described by Pollock and Davis in 1933,¹² then named by Keck in 1962¹³ and later by Lam.¹⁴ Entrapment may result from recent weight gain, posttraumatic fibrosis, chronic compres-

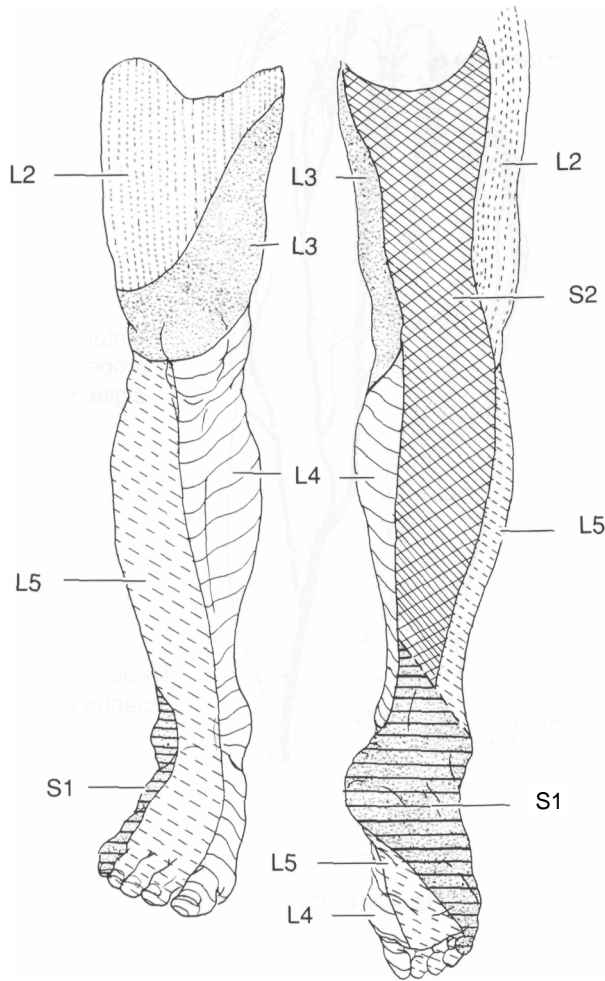


Fig. 28-5. Dermatome mapping of lumbar and sacral nerve roots.

sion from fascial bands, restriction within the lacinate canal, and entrapment by the abductor hallucis muscle¹⁵ (Fig. 28-8). It has also been postulated to occur in association with os trigonum syndrome.¹⁶ Goodman and Kehr¹⁷ reported 27 cases of bilateral tarsal tunnel syndrome, suggesting that it is more common than previously believed.

Symptoms consist primarily of sharp or burning paresthesia radiating into the plantar aspect of the foot aggravated by activity and relieved somewhat by rest and removing shoe gear. Proximal radiation is not uncommon, although not past the knee. Pain may occur

at night when the patient is in bed. Patients may also relate a feeling of "fullness" or "tightness" in the arch, while others complain of a sensation of impending arch cramps.¹⁸ The onset of the neuropathy is usually spontaneous or slow and insidious and may be mistakenly diagnosed as intermetatarsal neuromas.¹⁹

There is rarely any motor weakness detectable, although electromyograph (EMG) studies often demonstrate abnormal fibrillation potentials within the intrinsic muscles. Prolonged latency in the conduction of impulses along the medial and plantar nerves greater than 6.1 m/s and 6.7 m/s, respectively, help con-

firm the presence of a compression neuropathy.²⁰ Percussion of the posterior tibial nerve will almost always elicit a positive Tinel's sign as well as Valleix phenomenon. Turk's test, performed by inflating a thigh cuff to just below the systolic blood pressure, can exacerbate symptoms as the venae comitantes become engorged within the tarsal tunnel.²¹

Conservative measures include control of excess pronation, NSAIDs, massage, ultrasound, and the injection of steroid preparations or large volumes of local anesthetic into the third canal of the tarsal tunnel. If symptoms persist, then surgical decompression is indicated. The lacinate ligament must be incised over the third canal, followed by careful neurolysis, first proximally and then distally where the porta pedis is dilated as the nerve passes beneath the abductor hallucis muscle belly into the plantar vault. Tortuous veins in the area are excised and ligated. Only the superficial fascia is sutured, leaving the lacinate ligament open. A compression dressing is applied and the patient kept non-weight-bearing for no longer than 2 weeks so as to mobilize the tissues early. Postoperative Tinel's sign will usually diminish with time.²²

With symptoms generally the same, an extension of the tarsal tunnel syndrome involves entrapment or compression of the plantar nerves at the level of the abductor hallucis on entering the foot or beneath the midtarsus in the severely collapsed flatfoot. In the latter case, the patient may actually be placing full weight on the nerve through the bones of the tarsus. This is an extremely difficult condition to treat successfully. Conservative care involves using soft orthoses to distribute the weight away from the nerve. Surgery, when necessary, must not only free the nerve tissue but create some form of arch architecture through arthrodesing procedures to get the weight-bearing pressure off the nerve.

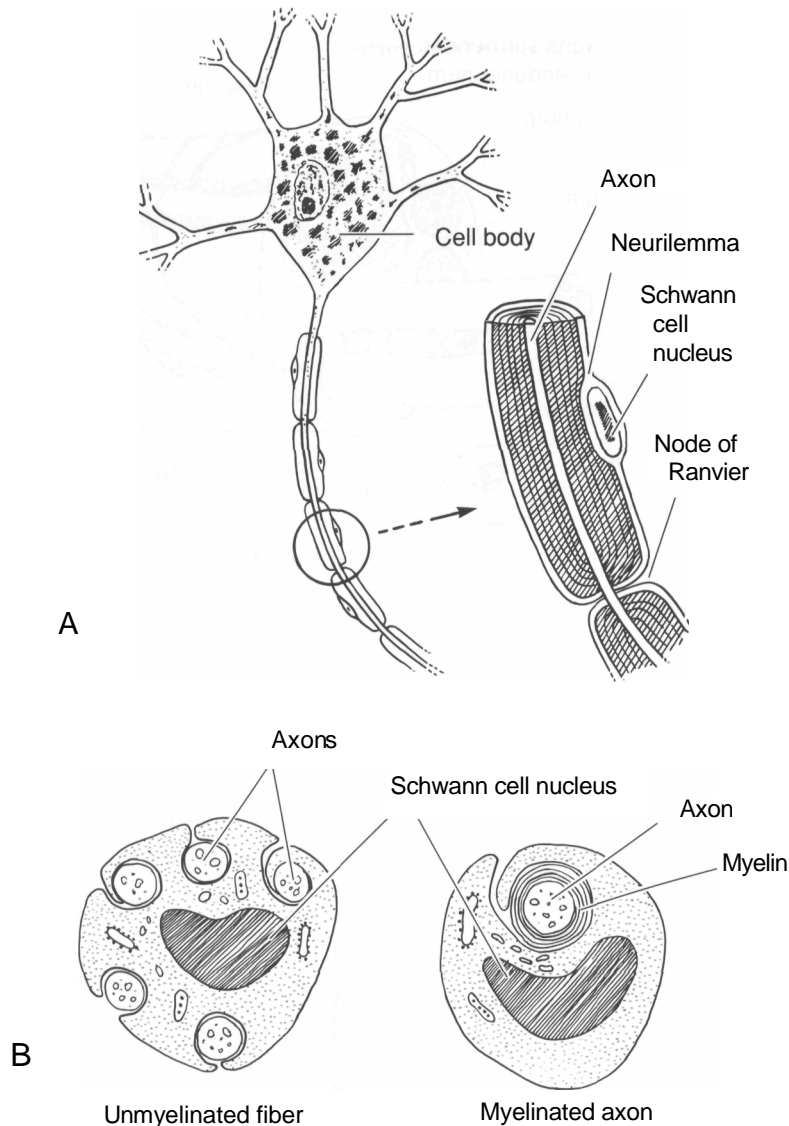


Fig. 28-6. Microanatomy of a nerve fiber. (A) Longitudinal section. (B) Cross section of myelinated axon and unmyelinated fiber with several unmyelinated axons enveloped by a single Schwann cell.

INFERIOR CALCANEAL NERVE ENTRAPMENT

Heel involvement has been reported as part of the tarsal tunnel syndrome,^{15,23} but generally this area is spared. However, patients with recalcitrant heel pain, with or without calcaneal spurs, have been shown to have good relief from decompression and neurolysis

of the inferior calcaneal nerve, the mixed sensorimotor branch to the proximal abductor digiti quinti muscle.^{24,26}

The most common origin of the inferior calcaneal nerve is from the lateral plantar nerve, where it is also known as the "first branch." The lateral plantar nerve gives off the first branch within or distal to the tunnel.²⁷

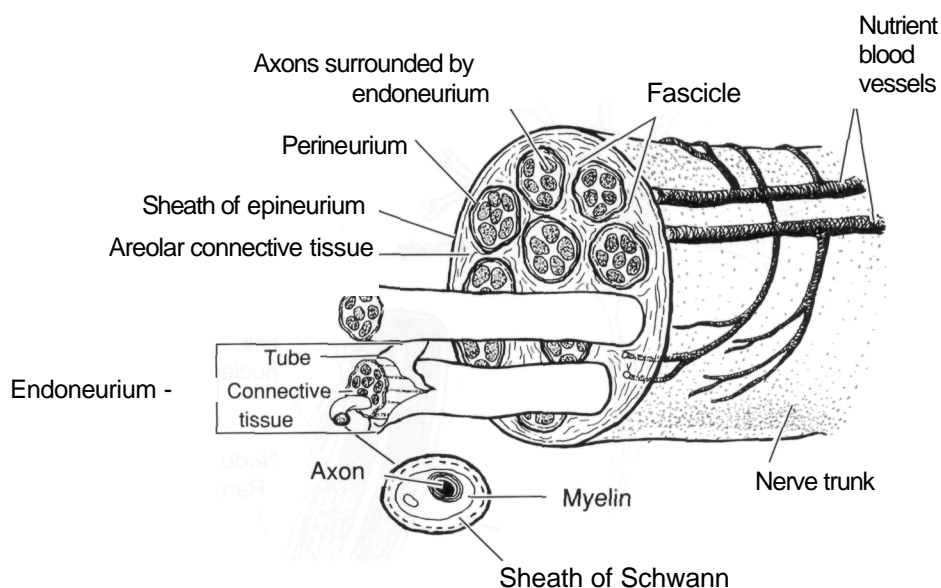


Fig. 28-7. Microanatomy of a peripheral nerve.

Except when involved in tarsal tunnel syndrome, entrapment of the inferior calcaneal nerve branch to the abductor digiti quinti muscle can cause severe and disabling heel pain. The nerve can be traumatized and compressed primarily at two sites: the firm fascial edge of the abductor hallucis muscle,^{28,29} and the me-

dial edge of the calcaneus where the nerve traverses either beneath the medial tuberosity or along the origin of the flexor brevis muscle and plantar fascia.²⁶

The symptoms usually differ from those of plantar fasciitis in that they include sharp, burning pain that often radiates up the posteromedial leg. It can be re-

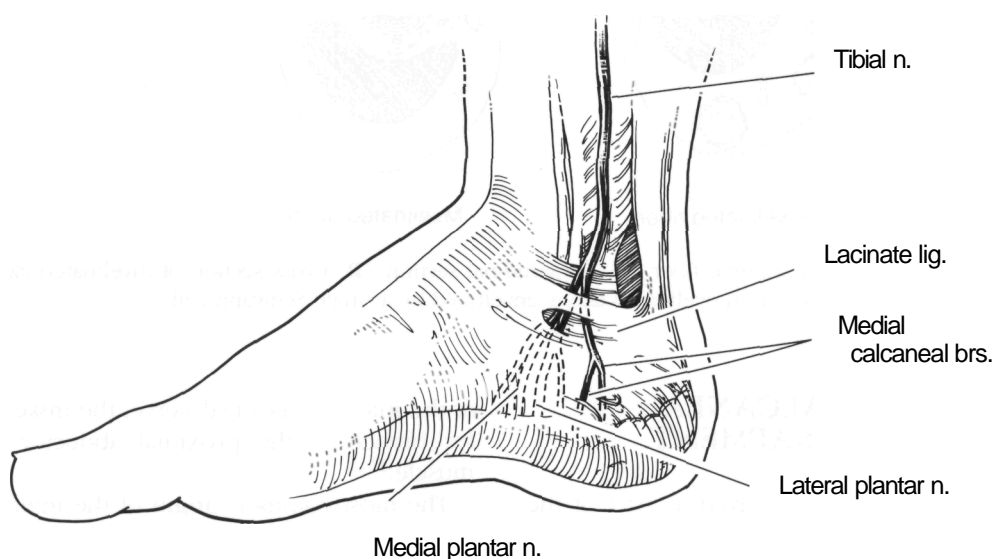


Fig. 28-8. Medial view of the foot showing branches of the posterior tibial nerve as they pass beneath the lacinate ligament through the third compartment of the tarsal canal.

produced by deep compression just medial or distal to the medial tuberosity. Patients frequently fail to experience the pain on weight-bearing after rest (poststatic dyskinesia) that is almost pathognomonic of the plantar fasciitis enthesopathy.

Pronation can be a great contributor to this entrapment but the syndrome also occurs in feet with normal or supinated architecture. Affected patients are commonly athletes or people whose occupations require long hours of standing or walking on concrete or other unforgiving surfaces. They characteristically do not respond to the variety of conservative therapeutic measures used to treat heel pain including rest, tape strapping, steroid injections, shoe adjustments, orthotic devices, ultrasound, and massage. In fact, many of these therapies tend only to aggravate the condition.

Surgery begins with a medial incision to access the nerve at, or distal to the medial tuberosity of the calcaneus. The deep fascia of the abductor hallucis muscle is released. The nerve is then freed along its course distal and deep to the medial tuberosity as it approaches the abductor digiti quinti muscle. The medial plantar fascia should be incised, and only a small portion of heel spur removed when present and only if it appears to be contributing to the entrapment. Results are often in the form of dramatic relief the next day. Patients should be kept non-weight-bearing for 2 weeks with a gradual return to full activity.

SURAL NERVE ENTRAPMENT

Entrapment of the sural nerve will cause sensory alterations and pain locally at the site of entrapment or all the way along its courses laterally to the fifth toe. Local trauma, surgical iatrogenic injury, and long-term chronic tendonitis of the tendo Achilles are the leading etiologies of this compression syndrome.²²

If symptoms are unresponsive to the usual conservative approaches, surgical intervention is frequently necessary. Neurolysis is the first choice for release but because the sural nerve is totally sensory, sectioning and excising the nerve are commonly necessary to alleviate the pain. Care must be taken to allow the nerve to retract into the shelter of soft tissues to prevent sensitive stump neuroma formation.

DORSAL FOREFOOT NERVE INJURY AND ENTRAPMENT

In addition to entrapment of the deep peroneal nerve on the dorsum of the foot, compression of the superficial peroneal nerve as it exits the deep fascia in the lower leg can cause painful symptoms. This nerve can also be trapped against dorsal exostoses along the course of its branches or can be injured by trauma.

Because many surgical approaches are via the dorsal foot, surgical trauma can result in painful sensory neuromas in that area. In one study, 19 of 25 (76 percent) of the neuromas occurred within the medial two-thirds of the dorsal midfoot, an area termed the neuromatous or N-zone (Fig. 28-9). Although nerves

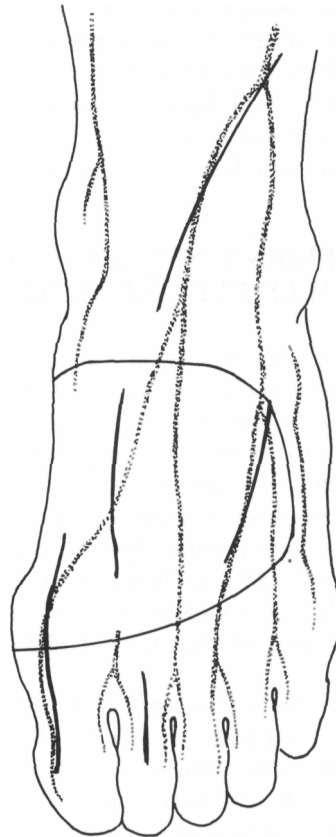


Fig. 28-9. Neuromatous or N-zone where incisions are more likely to lead to symptomatic neuromas. (Adapted from Kenzora,³⁰)

are frequently damaged in bunion surgery, they are seldom symptomatic. In addition, toe surgery rarely results in painful neuromas or nerve injuries.³⁰

Once identified, nerves trapped in scar tissue can be treated by injection therapy using enzyme mixtures, sclerosing solutions,³¹ steroid preparations, or volume injection adhesiotomy techniques.³² If they remain painful, they are best treated by neurolysis and excision. This is a technically difficult and often painful approach that can yield up to 26% unsatisfactory results.³³ The conclusion is that it is much easier to prevent a sensory neuroma by careful surgical technique than to treat a highly symptomatic neuroma. This requires thoughtful planning for the location of the incision, gentle tissue separation and retraction, identification and visualization of peripheral nerves, and judicious suturing technique.

Symptoms can also occur on the dorsal foot when the superficial peroneal nerve suffers a traction injury, as in an ankle sprain, or entrapment at the fibular neck^{34,35} or where it exits the deep fascia in the anterior lower leg.³⁶ Local injury can occur from contusions, fractures, or midfoot exostoses, or by compression from adjacent soft tissue masses such as ganglia.

ENTRAPMENT NEUROPATHY OF THE DEEP PERONEAL NERVE

Compression neuropathy involving the anterior tibial or deep peroneal nerve has been described as "anterior tarsal tunnel syndrome."³⁷ It may be an entrapment of the nerve at the inferior extensor retinaculum.^{38,39} (Fig. 28-10) It can also be caused by traction, trauma, local exostoses, edema, or shoe pressure. Altered sensation in the first web space is the hallmark diagnostic sign.⁴⁰ EMG studies may reveal distal latency in the deep peroneal nerve, and there may be signs of denervation in the extensor digitorum brevis muscle.

Treatment includes avoidance of shoe pressure, steroid injections, and pads to disburse direct pressure on the nerve. If conservative therapy fails, surgical intervention for relief of symptoms includes exostectomy, neurolysis, or retinacular release. In one study where entrapment release was performed on 20 nerves in 18 patients followed for a mean of 25.9

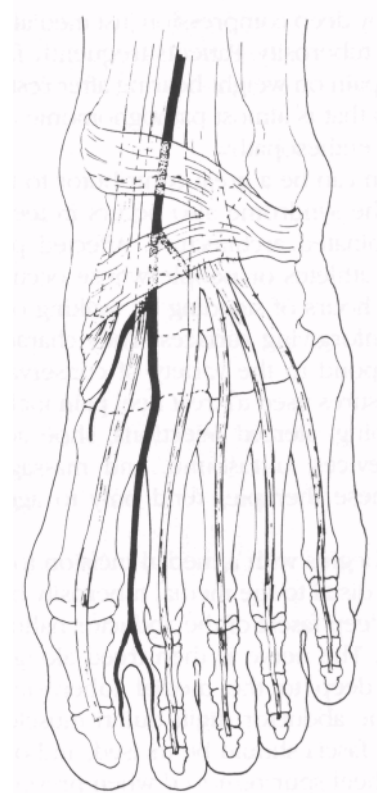


Fig. 28-10. Deep peroneal nerve anatomy.

months, operative results were excellent in 60 percent, good in 20 percent, and not improved in 20 percent.⁴¹

ENTRAPMENT NEUROPATHY ABOUT THE FIRST METATARSOPHALANGEAL JOINT

There are four nerve branches crossing the first metatarsophalangeal joint, corresponding roughly to the four corners of the hallux. The dorsolateral surface is supplied by the deep peroneal nerve; its pathology is described elsewhere.

Joplin⁴² described a perineural fibrosis of the proper digital nerve as it coursed along the plantome-

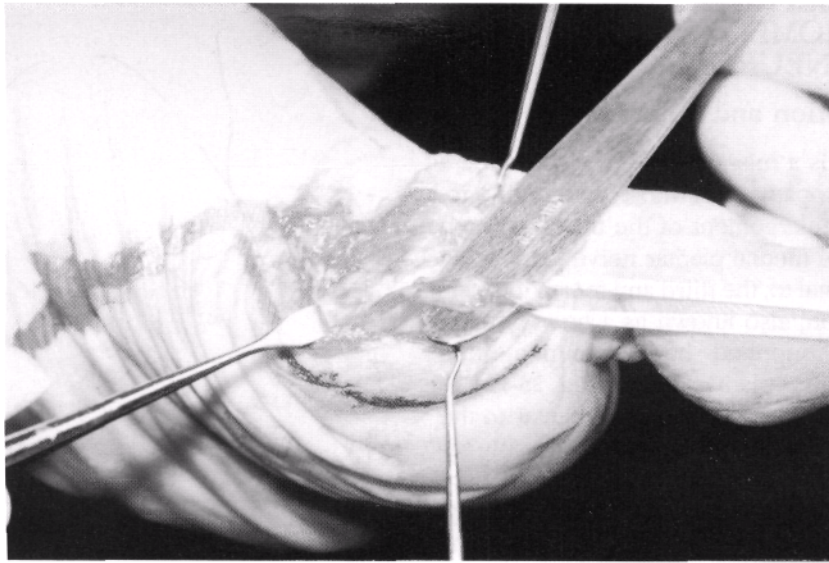


Fig. 28-11. Example of a Joplin's neuroma dissected from beneath the medial edge of a bunion.

dial first metatarsal head. He reported the removal of 265 of these entities.⁴² The nerve either displaces laterally from its usual anatomic position or, in the course of the development of hallux valgus deformity, the metatarsal head drifts medially to bear weight directly on top of the nerve. Pronatory forces that concentrate body weight through the medial foot provide further compressive forces that stimulate perineural edema and fibrosis, axon degeneration, and Renaut body formation. The result is pain, paresthesia, and numbness.

Treatment with pads and orthotics to redistribute body weight will help relieve pressure on the nerve. Steroid injections can be helpful and anesthetic infiltration diagnostic. Surgery is the curative treatment by means of a neurectomy through a medial approach at the junction of the dorsal and plantar skin. Clean transection of the proximal nerve trunk under tension will allow the nerve end to retract into the abductor hallucis muscle belly for protection⁴³ (Fig. 28-11).

Another location for entrapment compression neuropathy is the dorsomedial first metatarsophalangeal joint.⁴⁴ The most medial branch of the medial dorsal cutaneous nerve becomes compressed between an enlarged medial eminence and the shoe, and very little enlargement is necessary to develop the problem.

Avoidance of shoe pressure, padding, injection therapy, and bunionectomy will all help alleviate the pressure. At times nerve excision is necessary to relieve painful paresthesia unresponsive to other forms of treatment. Similar neuromas can be found in association with tailor's bunions where treatment is generally the same.⁴⁵

Intermetatarsal plantar neuromas are rarely found between the first and second metatarsal heads, only 3.9 percent in one study.⁴⁶ Such a painful lesion can remain after corrective bunion surgery, having been overseen as contributing to the patient's symptoms preoperatively. Hypermobility is part of the cause of intermittent nerve compression, but a contributing factor can be the laterally displaced fibular sesamoid impinging the nerve against the second metatarsal head. Neuralgic symptoms are the result.

Failure of conservative treatment requires surgical excision through a dorsal or plantar approach, or a fibular sesamoidectomy. Again, the nerve trunk must be sharply divided and allowed to retract into the intrinsic muscle bellies. The patient must be made aware of the areas of anesthesia that will result.

INTERMETATARSAL NEUROMA SYNDROME: MORTON'S NEUROMA

Definition and Anatomy

Morton's neuroma is a misnomer used to describe a painful pedal neuropathy that most commonly appears as a benign enlargement of the third common digital branch of the medial plantar nerve located between, and often distal to, the third and fourth metatarsal heads. The lesion, also known as a *perineural fibroma*, is usually supplied by a communicating branch from the lateral plantar nerve⁷ (Fig. 28-12).

Classically, the involved nerve passes plantar to the deep transverse intermetatarsal ligament. The only additional structures traversing this immediate area are the third plantar metatarsal artery with its accompanying vein or veins, and the tendon slip from the third lumbrical muscle that inserts into the extensor hood apparatus on the medial aspect of the fourth toe. This perineural fibroma is separated from the sole by the subcutaneous fat pad, plantar fascial slips, and connective tissue compartments (Fig. 28-13). Frequently, there is found, either alone or in close association with Morton's neuroma, an intermetatarsal bursa that

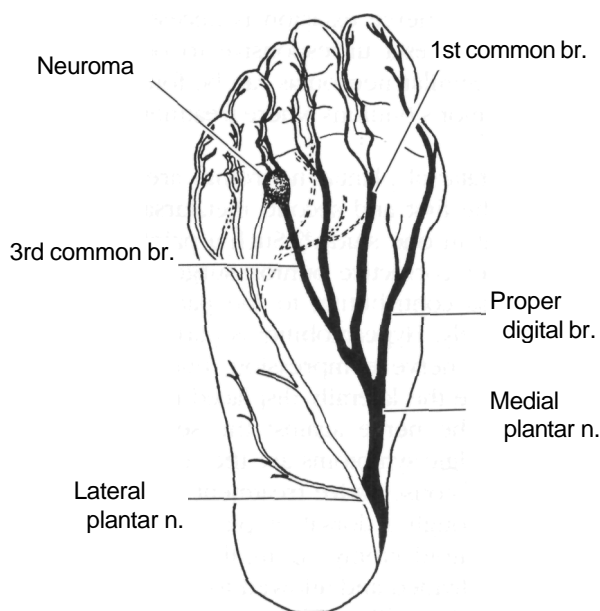


Fig. 28-12. Classic site of Morton's neuroma in relationship to the plantar nerves.

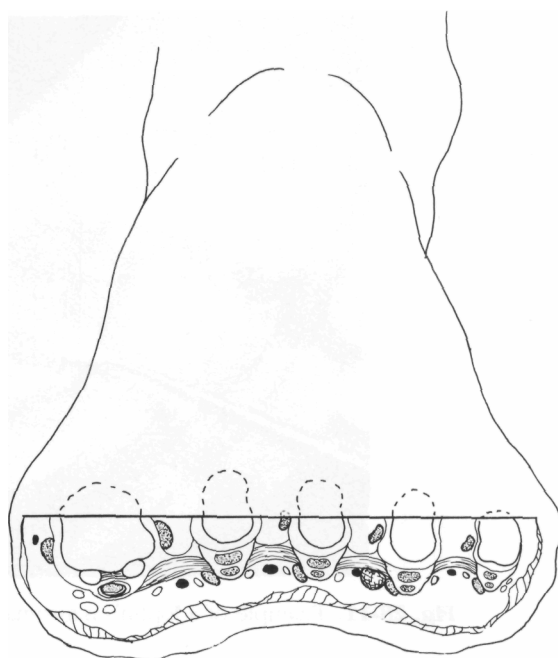


Fig. 28-13. Cross section through the forefoot at the level of the metatarsophalangeal joints.

is deep and usually distal to the deep transverse intermetatarsal ligament (Fig. 28-14).⁴⁷⁻⁵⁰

Interestingly, this is also the area in which pacinian corpuscles are normally found in the subcutaneous tissues,⁵¹ and it is common to find multiple sensory branches diving plantarly from the nerve trunk and/or neuroma at the time of dissection. As an observation, these usually are found in the patients with the greater neuralgic symptoms causing the metatarsalgia.

Histopathology

Summarized in Table 28-2 is the microscopic pathology of Morton's neuromas.⁵²⁻⁶¹ Many of these findings are also found in "normal" plantar nerves after years of wear and tear; endoneurial edema, exceptional fibrosis and demyelination are diagnostic of Morton's neuroma^{62,63} (Fig. 28-15). Serial section analysis has revealed that these degenerative nerve changes are usually found distal to the deep transverse intermetatarsal ligament.⁶⁴

Investigators have found that a neuroma does not have to be particularly large or be present for a long

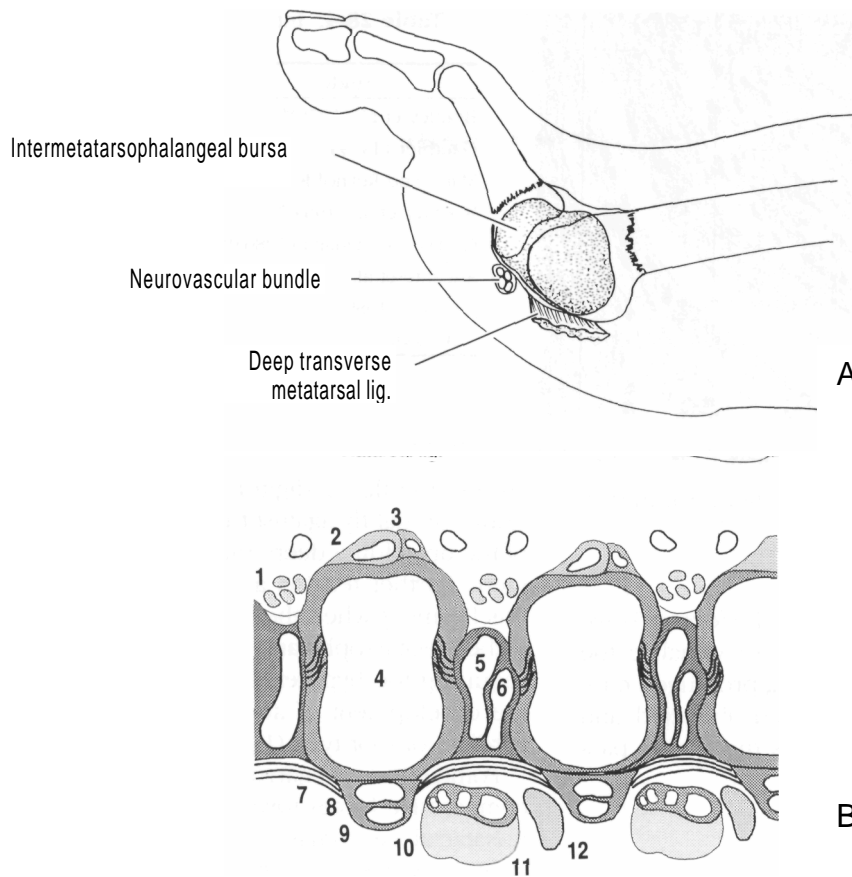


Fig. 28-14. (A) Longitudinal section through third intermetatarsal space. (B) Frontal section through bases of proximal phalanges. There is no bursa in the lateral web space.

- | | |
|-------------------------------|--|
| 1. Neurovascular bundle | 7. Deep transverse metatarsal ligament |
| 2. Long extensor tendon | 8. Long flexor tendon |
| 3. Short extensor tendon | 9. Short flexor tendon |
| 4. Metatarsal head | 10. Neurovascular bundle |
| 5. Dorsal interosseus muscle | 11. Adipose tissue |
| 6. Plantar interosseus muscle | 12. Lumbrical |

time to undergo pathologic changes and cause painful symptoms.^{58,65,66} Except for Reed and Bliss⁴⁷ and Hauser,⁶⁷ no researchers have found any histologic evidence of inflammation in a neuroma.^{58,60,68}

Etiology and Biomechanics

Recent published information leaves little doubt that the syndrome of intermetatarsal neuroma is indeed a mechanical entrapment neuropathy^{52,63,64,69} with degenerative changes that are largely the result of both stretch and compression forces. In reference to the

development of fibrosis within nerve support structures, Goldman⁵³ suggested that the epineurium responds to mechanical compression whereas the perineurium responds to stretch.

The next question: what is the source of these mechanical forces? A common observation is that the majority of intermetatarsal neuromas occur in the pronated foot,^{65,70-72} where there are not only excessive stretch forces imposed on the interdigital nerves but also compressive and shearing forces from adjacent hypermobile metatarsal heads.⁷³⁻⁷⁵

Observing that the medial and lateral plantar nerves

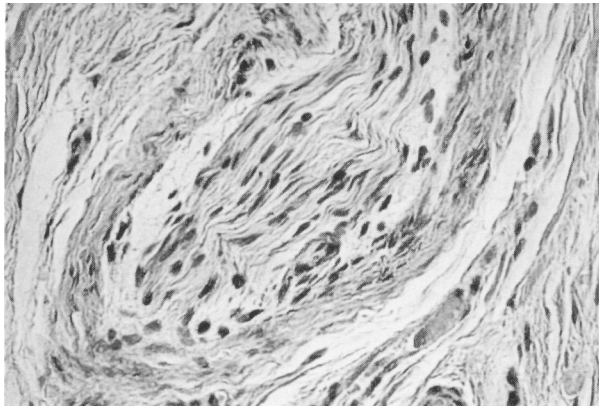


Fig. 28-15. Photomicrograph of cross section through Morton's neuroma (H & E, X100.)

pass down the posteromedial side of the foot and dive plantarly under the arch, it is easy to visualize the stretch placed on these nerves during prolonged mid-stance pronation as the foot is everted, abducted, and dorsiflexed. Tension is increased as the nerves pass

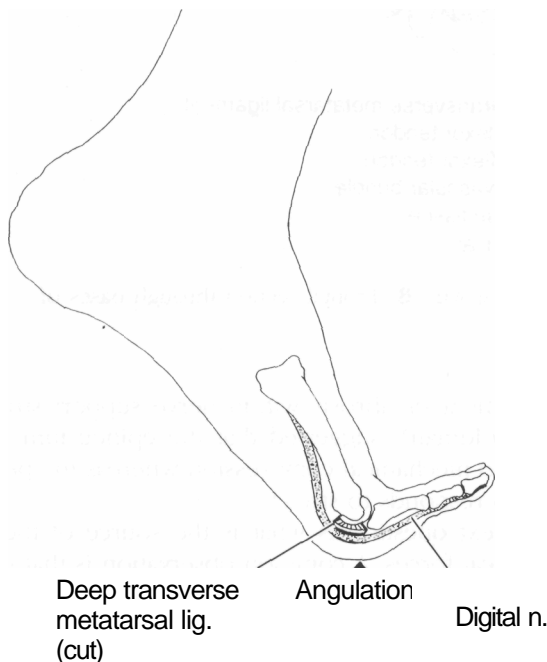


Fig. 28-16. Toe hyperextension causes stretch of interdigital nerves and tension against deep transverse metatarsal ligaments.

Table 28-4. Intermetatarsal Neuromas: Distribution by Sex

Study	Male	Female	<i>n</i>
Bradley et al. (1976) ⁸¹	14 (16%)	71 (84%)	85
Gauthier (1979) ⁸²	19 (9%)	187(91%)	206
Mann and Reynold;, (1983) ⁸³	3 (5%)	53 (95%)	56
Wachter et al. (1984) ⁸⁰	? (17%)	? (83%)	?
Gudas and Mattana (1986) ⁸⁴	7 (16%)	36 (84%)	43
Addante et al. (1986) ⁴⁶	27 (20%)	109(80%)	136
Johnson (1989) ¹²²	? (22%)	? (78%)	124
Average	15%	85%	

around the flexor digitorum brevis "sling"⁷⁶ and are drawn up tightly against the plantar and anterior edge of the unyielding deep transverse intermetatarsal ligament. Further tension and compression will occur at this ligament when the toes hyperextend or dorsiflex at the metatarsophalangeal joint.^{8,64,66,76-80} Occupations requiring toe hyperextension can therefore result in the development of an intermetatarsal neuroma, regardless of foot type (Fig. 28-16).

Pointed-toe or narrow shoes can definitely add compressive forces toward the development of intermetatarsal neuromas.^{76,78} High-heeled shoes will not only throw weight forward onto the ball of the foot, jamming it into the narrow toe box, but will also force the toes into hyperextension and thus contribute to the entrapment etiology.

Diagnosis

Morton's neuroma is classically and most commonly found in the third intermetatarsal space in females (Table 28-4). Otherwise known as an intermetatarsal neuroma, it also develops frequently in the second intermetatarsal space but rarely in the first or fourth (Table 28-5). Although it usually presents as a single

Table 28-5. Intermetatarsal Neuromas: Location

Study in %	1st	2nd	3rd	4th	Other
Wachter et al. (1984) ⁸⁰		43	57	—	—
Gudas and Mattana (1986) ⁸⁴		5.1	86.4	8.5	—
Addante et al. (1986) ⁴⁶	3.9	17.8	66.4	2.6	9.2
Johnson (1989) ¹²²	—	16	84		

Table 28-6. Intermetatarsal Neuromas: Occurrence

Study	Single (%)	Double (%)	Bilateral (%)	Repeat (%)	(n)
Bradley et al. (1976) ⁸¹	63	4	27	6	85
Gauthier (1979) ⁸²	42	23	35	—	304
Mann and Reynolds (1983) ⁸³	61	—	39	15	76
Gudas and Mattana (1986) ^{84*}	63	11	26	—	43
Johnson (1989)	82	2	14	—	149
Average	62	10	28	11	

entity, more than one intermetatarsal neuroma may develop in the same foot or both feet⁸⁵⁻⁸⁸ (Table 28-6). The lesion is most commonly diagnosed between the fourth and sixth decades and the patient is likely to be overweight.^{51,72} Symptoms may be present from a few weeks to several years.

The patient may initially describe a sensation as if walking on a wrinkle in her stocking or a lump in her shoe. In more advanced cases, the pain may be sharp, dull, or throbbing, but classically presents as paroxysmal burning "like walking on a hot pebble" or "having a hot poker thrust between the toes."

The pain is most often localized to the region of the third and fourth metatarsal heads and may radiate distally into adjacent toes, especially the fourth, or proximally up the leg to the knee. Numbness in the third and fourth toes may be the presenting symptom; however, there is seldom a sensory deficit. Sometimes, patients describe a "cramping" sensation in the arch or toes but there is no physical evidence of cramping^{83,86} (Table 28-7).

The pain is greatly aggravated by walking in shoe gear and is relieved somewhat by rest. Pathognomonic is the overwhelming desire to remove the shoe, massage the forefoot, and flex the toes although relief is only transient. Occasionally, the pain persists at rest and at night the patient might even find that pressure from the bed sheets is intolerable.

In many cases, acute pain symptoms appear after an incident of trauma. Examples include stepping on a rock, twisting an ankle, jamming the foot into the floorboard in a motor vehicle accident, or simply changing into a pair of new shoes and doing an extraordinary amount of walking. Narrow or tight-fitting shoes can both instigate and aggravate pain symptoms. Occupations that mandate repetitive foot stress, such

as working a pedal, walking on concrete, or squatting, can incite neuroma pain.

The intermetatarsal spaces are often tender to direct plantar palpation. A thickened nerve cord can frequently be rolled against a thumb over the distal metatarsal heads in the plantar sulcus when the toes are dorsiflexed. This may reproduce a varying amount of pain.

Dorsoplantar palpation of the affected intermetatarsal space with simultaneous side-to-side compression of the metatarsal heads (the "lateral squeeze test") can reproduce the pain by directly trapping the neuroma with pressure (Fig. 28-17). When lateral compression of the metatarsal heads elicits a silent, palpable, and sometimes painful "click," Mulder's sign is said to be positive.⁸⁷ However, the intermetatarsal bursa can also be responsible for the click.⁸⁸

Electrodiagnostic techniques for evaluating Mor-

Table 28-7. Preoperative Symptoms of Morton's Neuroma

Symptoms	Neuromas [n = 65 (%)]		Recurrent Neuromas [n = 11 (%)]	
Pain radiating to toes	40	62	4	36
Burning pain	35	54	4	36
Aching or sharp pain	26	40	7	63
Pain up foot or leg	22	34	2	18
Relief by removing shoe	46	70	6	54
Relief by rest	58	89	11	100
Cramping sensation	22	34	0	0
Pain increased with walking	59	91	11	100
Plantar pain	50	77	11	100
History of associated injuries	10	15	1	9
Numbness into toes or foot	26	40	2	18

(From Mann and Reynolds.⁸³ with permission.)

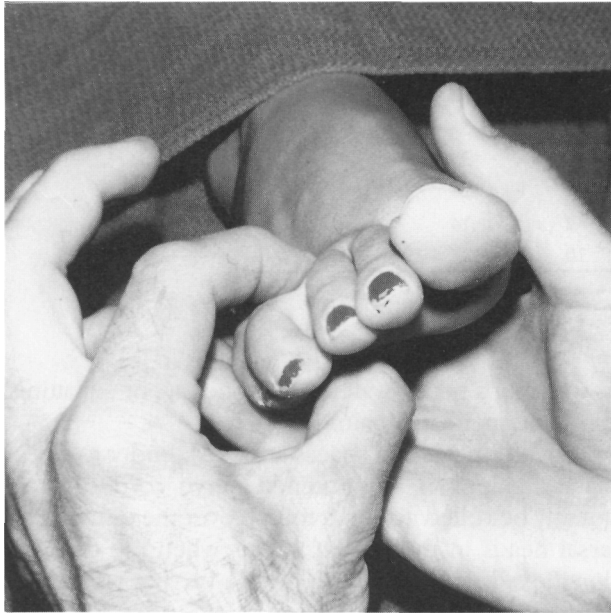


Fig. 28-17. The "lateral squeeze test" is positive when the maneuver reproduces pain symptoms.

ton's neuroma are not precise because of the difficulty in isolating a single interdigital nerve with an electrode to measure sensory conduction velocity.⁶³ However, in one such study the diagnosis was confirmed by electrophysiologic testing of five patients. Positive results were characterized by an "abnormal dip phenomenon," a relatively normal nerve conduction velocity, and normal duration of the sensory compound nerve action potential. These findings are the hallmarks of a neuropathy with predominantly axonal degeneration.⁸⁹

The differential diagnosis of Morton's neuroma includes metatarsal stress fractures, tarsal tunnel syndrome, nerve root compression syndromes, metabolic peripheral neuropathy, localized vasculitis, ischemic pain, intermetatarsal bursitis, rheumatoid arthritis, and osteochondritis dissecans of metatarsal heads.

Weight-bearing radiographs should be taken to rule out other pathology. However, the neuroma itself is not visible on x-ray films or xeroradiographs. Morton's neuroma can be defined using MRI. Because this is a costly test, it should be ordered judiciously for difficult cases.⁹⁰ Neuromas have also been visualized in high-resolution ultrasound studies.⁹¹

Conservative Management

Initial measures for treatment should be directed toward reducing or preventing irritation of the neuroma. Wider shoes with good arch support and adequate toe room provide the simplest approach. Avoiding high heels can be helpful but most patients have already discovered this. Toe crests sometimes provide relief. Metatarsal pads set at the proximal edges of metatarsal heads two, three, and four will help splay the bones and draw the weight proximally off the neuroma (Fig. 28-18). Several padding techniques have been described,⁹²⁻⁹⁷ which can be com-

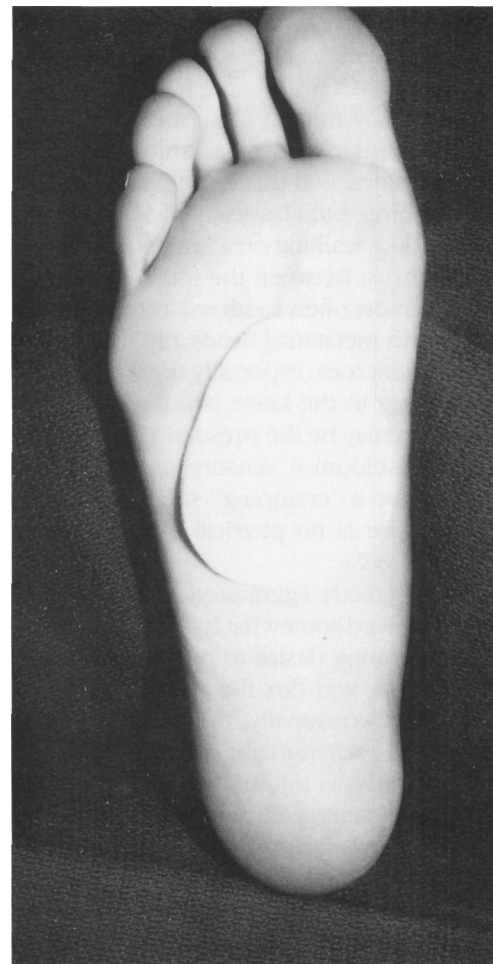


Fig. 28-18. Placement of a metatarsal pad to treat Morton's neuroma.

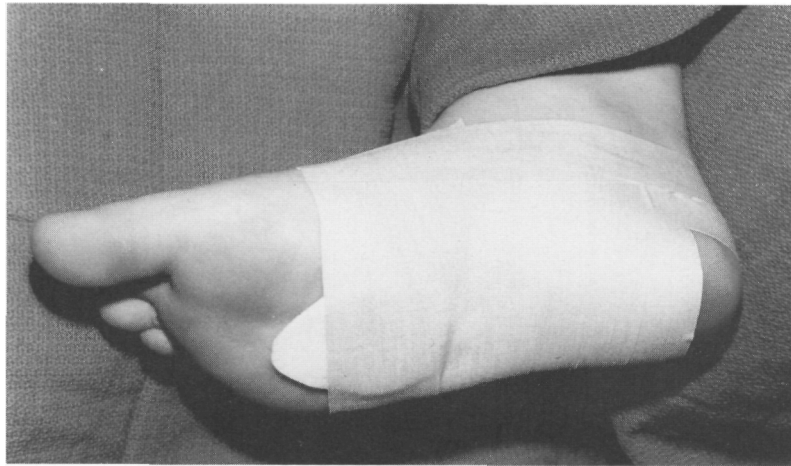

Fig. 28-19. Low-dye strapping with metatarsal pad to relieve metatarsalgia.

bined with a low-Dye strapping to add more support (Fig. 28-19). If pads and strappings are successful, then cast-fitted neutral position orthoses can be helpful. The goal is to limit pronation and hypermobility of the forefoot, both of which cause painful irritation of the neuroma.⁹⁸⁻¹⁰¹

Using proper techniques, injection therapy can provide a measure of relief.³¹ Vitamin B₁₂ or cyanocobalamin infiltration, advocated by one author,¹⁰² resulted in some success although the relief may have been due to the sclerosing effects of the preserving agent, 1 percent benzoyl alcohol.

The use of a local anesthetic by itself acting as a nerve block is rarely therapeutic, but can give helpful diagnostic information. It is especially useful for differentiating more proximal neuropathies such as spinal radiculopathies.

Injection therapy has been described by several writers using various steroid preparations combined with local anesthetic agents.¹⁰³⁻¹⁰⁵ Starting dorsally, infiltration should be directed between the metatarsal heads, injecting before and after penetration of the deep transverse intermetatarsal ligament, then distally into the sulcus area (Fig. 28-20). The patient should be cautioned that the symptoms may even get worse for 1 or 2 days before the desired effects are obtained. This so-called "steroid flare" is seen especially when less soluble steroid salts are utilized. Pain may also be accentuated if there is direct injury to the nerve tissue by the needle.

Finally, infiltration with a dilute 4 percent alcohol solution can be effective when the neuroma has a chronic history, using approximately 1 ml per infiltration to provide the necessary sclerosing effect. This solution is made by withdrawing 2 ml from a 50-ml vial of 2 percent lidocaine and replacing it with 2 ml alcohol USP (ethanol, ethyl alcohol). Care must be taken when increasing the percent alcohol strength because the infiltration of pure alcohol has led to disastrous results, including sloughing of the skin and intervening tissues.¹⁰⁶

Surgical Management

Indications

When conservative measures fail and painful symptoms persist, surgical excision becomes the treatment of choice.^{67,48,50,60,77,78,86,87,96,101,107-110} Although no well-controlled studies have been reported analyzing and comparing the conservative approaches to intermetatarsal neuromas, except for mixed results from injection therapy, it is the general experience that only 20 to 30 percent of symptomatic patients respond to non-operative measures. Patients should be made aware of this early in their management program, because the majority will likely elect surgical resection for relief of their painful symptoms. Even with surgical intervention, however, as many as 24 percent of the patients will have unsatisfactory results.⁸¹⁻⁸⁴

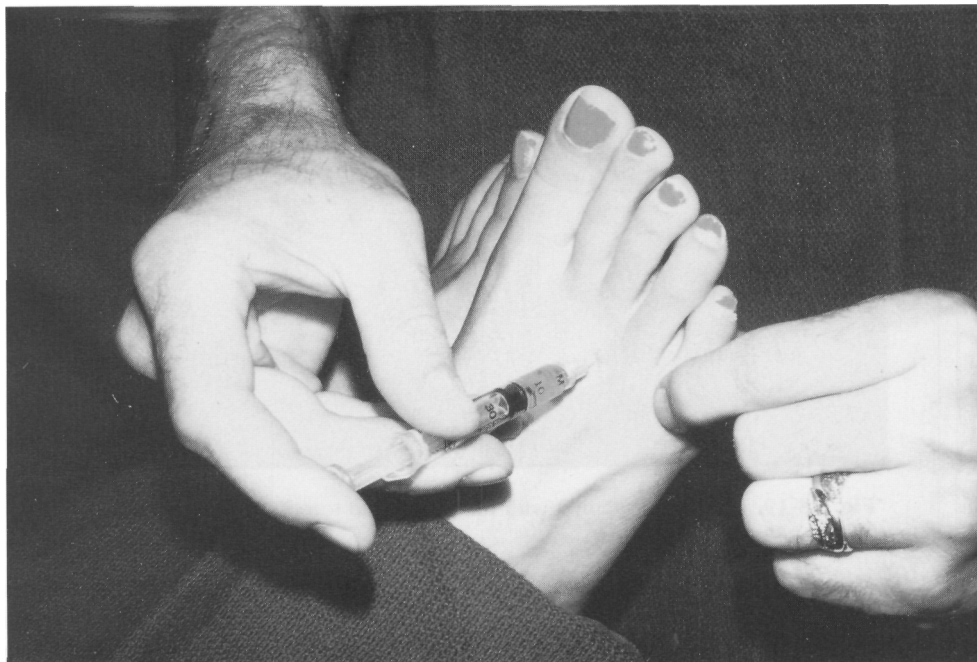


Fig. 28-20. Injection therapy for treatment of intermetatarsal neuroma.

Surgery is usually performed in an outpatient setting under general, regional, or local anesthesia. When excised under local anesthesia, field infiltration should be augmented with a posterior tibial nerve block to prevent the lancinating pain that can occur when the proximal nerve trunk is sharply severed.

Four approaches have been described for access to the intermetatarsal neuroma: plantar longitudinal,^{76,77,87,111} plantar transverse,^{55,111} web-splitting,^{78,102} and dorsal^{112,113} (Fig. 28-21): all have advantages and disadvantages. The two most frequently used techniques are described here.

Plantar Approach

The second most common approach is via plantar longitudinal incision. This approach provides the best exposure to the neuroma and leaves the deep transverse intermetatarsal ligament intact. The disadvantage is the potential for a painful plantar scar on the weight-bearing surface. Prophylaxis against this includes careful placement of the incision between the metatarsal heads as well as 3 weeks of absolutely no weight-

bearing postoperatively.⁷ Excision via plantar approach has achieved a 93 percent success rate in one study.¹¹⁴

Once the plantar incision is made and hemostasis achieved, minimal dissection will expose the entire neuroma. Vascular structures are easily identified and preserved, and the deep transverse intermetatarsal ligament is left undisturbed because the neuroma lies plantar to it. The digital branches are isolated and clearly transected, followed by the proximal nerve trunk and, if present, accessory branches. Using vertical mattress sutures, deep closure is made with little or no dead space (Fig. 28-22).

Dorsal Approach

The more common dorsal approach has the advantage of allowing early ambulation because the incision is on a non-weight-bearing surface (Fig. 28-23). There is some disadvantage in the initial awkwardness of dissecting deep between the metatarsal heads as well as having to sever the deep transverse intermetatarsal ligament. These tasks are facilitated with the use of the

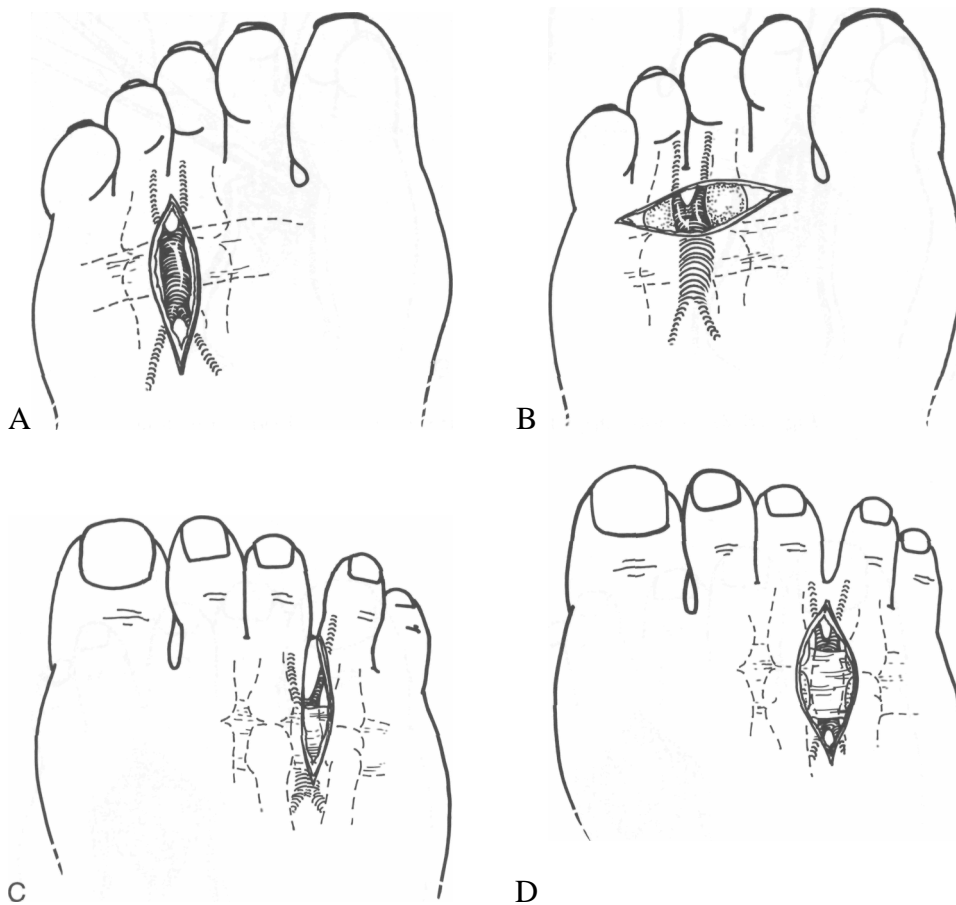


Fig. 28-21. (A—D) Incisional approaches for resection for Morton's neuroma.

Schink metatarsal spreader (Fig. 28-24). There is also greater potential for dead space.⁷

After the initial dorsal incision over the intermetatarsal space, blunt dissection is carried down to the deep transverse intermetatarsal ligament, which is sharply incised. The metatarsal spreader is inserted for maximum exposure. Gentle finger pressure on the plantar sulcus will deliver the fusiform neuroma into the wound so the digital branches can be isolated, clamped, and cut distally (Fig. 28-25). Vascular structures must be identified and divided for hemostasis only when necessary. The neuroma is then dissected as far proximal as possible, placed under tension, and cleanly transected along with any other communicating branches present (Fig. 28-26). Keeping the blade "coaxial" to the neuroma will help preserve local vas-

cular and tendon structures. Routine closure should include a large over-and-over suture through adjacent capsules to bring the metatarsal heads close together and allow healing of the deep transverse intermetatarsal ligament. A closed suction drain can be inserted if necessary.

Deep Transverse Intermetatarsal Ligament

The role of the deep transverse intermetatarsal ligament has raised some interesting issues. Gauthier⁸² achieved an 83 percent overall success rate by simply transecting the ligament (which he identified as plantar fascia) and then performing microscopic epineural neurolysis. Bradley et al.⁸¹ achieved better results when the neurectomy was combined with percuta-

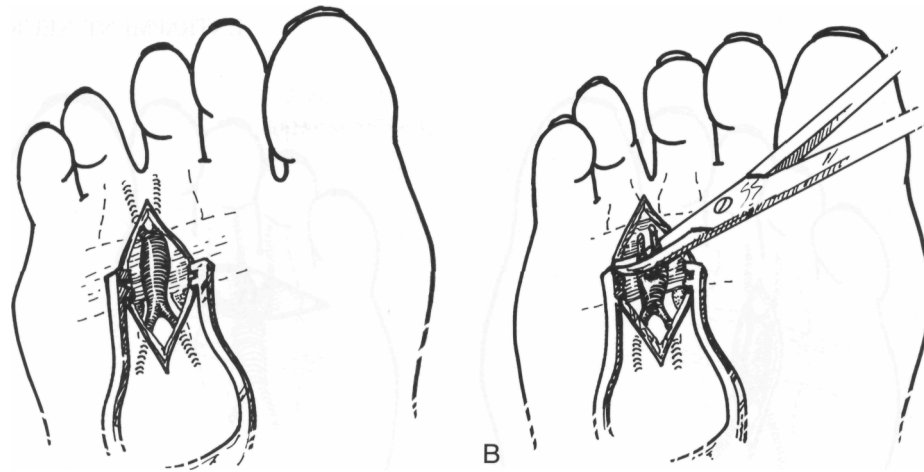


Fig. 28-22. Plantar approach for resection of Morton's neuroma.

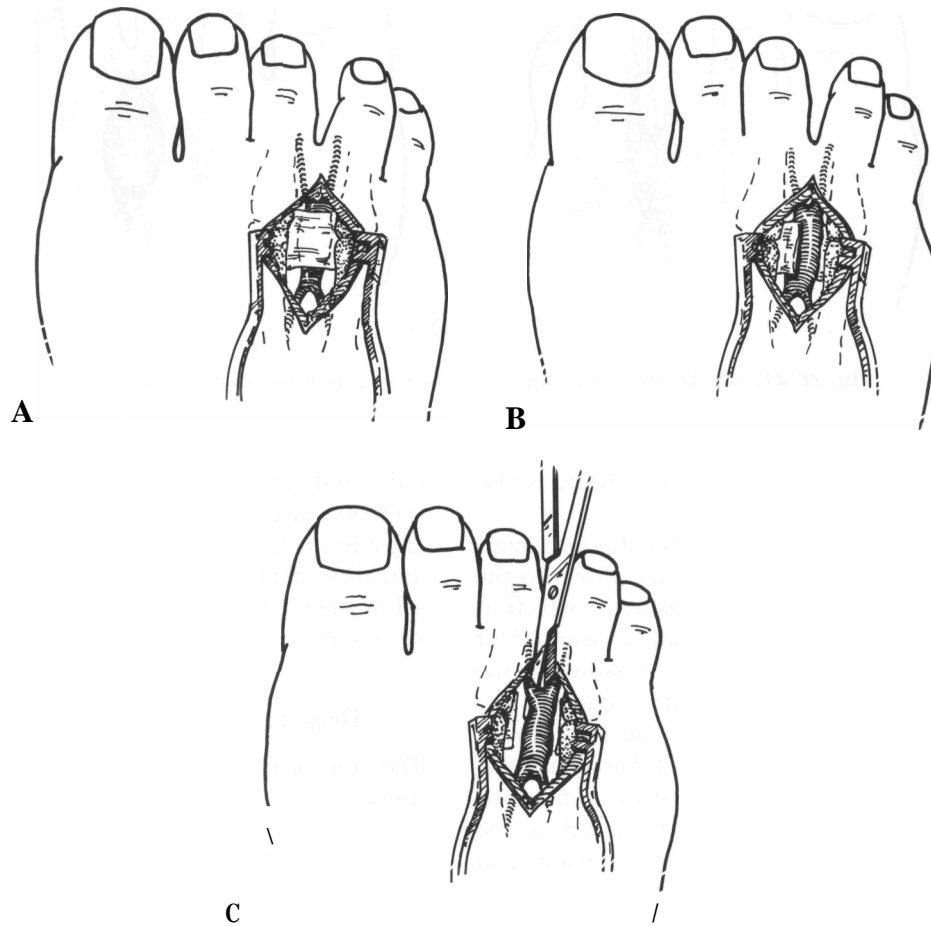


Fig. 28-23. (A-C) Dorsal approach for resection of Morton's neuroma. (*Figure continues.*)

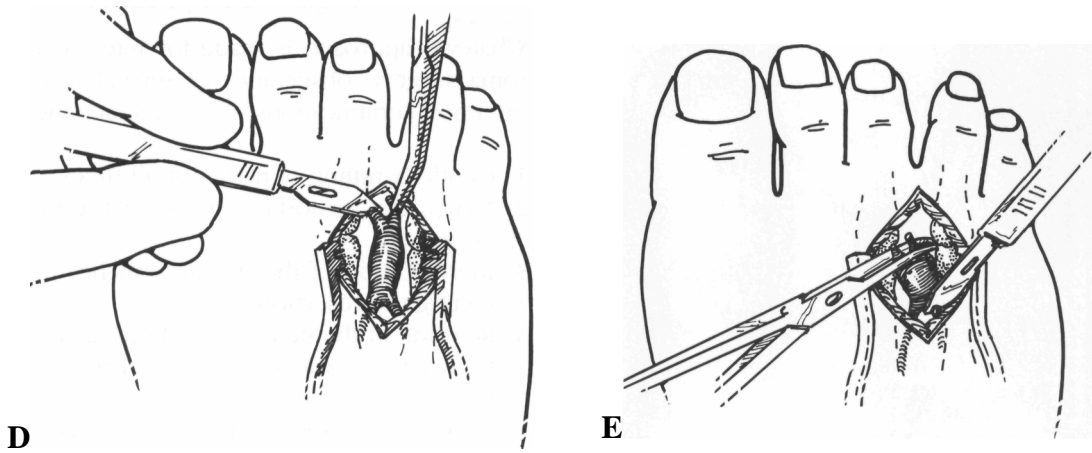


Fig. 28-23 (Continued). (D & E).

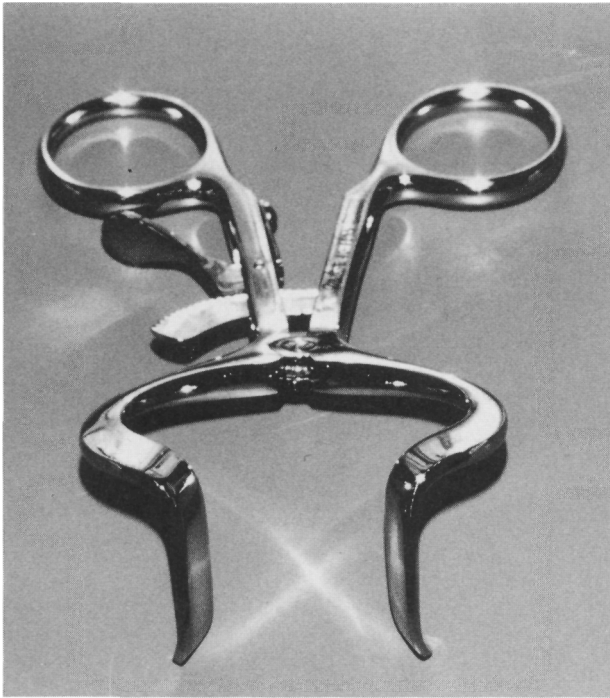


Fig. 28-24. Schink metatarsal spreader. Strong, thin blades allow ease of introduction into the surgical site to spread the metatarsal for less traumatic access to the proximal trunk for the neuromas. (Courtesy of Miltex Instrument Company, Inc., 6 Ohio Drive, Lake Success, NY, 11042; instrument number 40-1235.)

neous fasciotomy: 83 percent as compared to 66 percent without combining. Gudas and Mattana⁸⁴ reported good to excellent results in 79 percent of their series, in which the neuromas were excised via dorsal approach leaving the said ligament intact.

It is important to preserve the function of the deep transverse ligament as it provides a fulcrum around which the lumbrical tendon stabilizes the lesser toes. When this tendon loses its functional ability, the affected lesser toe begins a dorsal contracture at the proximal phalanx until the extensor tendon and hood apparatus acquire function. The result is a full hammer toe deformity. Suturing the adjacent capsules will bring the metatarsal heads close enough for the ligament to heal. In reoperating on recurrent neuromas, Mann and Reynolds⁸³ noted complete reconstitution of the deep transverse intermetatarsal ligament that had been sectioned at the initial surgery.

Adjacent Interspaces

Because neuromas can occur in adjacent intermetatarsal spaces, excision of both neuromas simultaneously adds to the risk of vascular embarrassment. Separate incisions should be kept as far apart as possible to avoid necrosis of the intervening skin. When using a single incision, the incorporation of curves will make allowance for scar contracture and help prevent digital

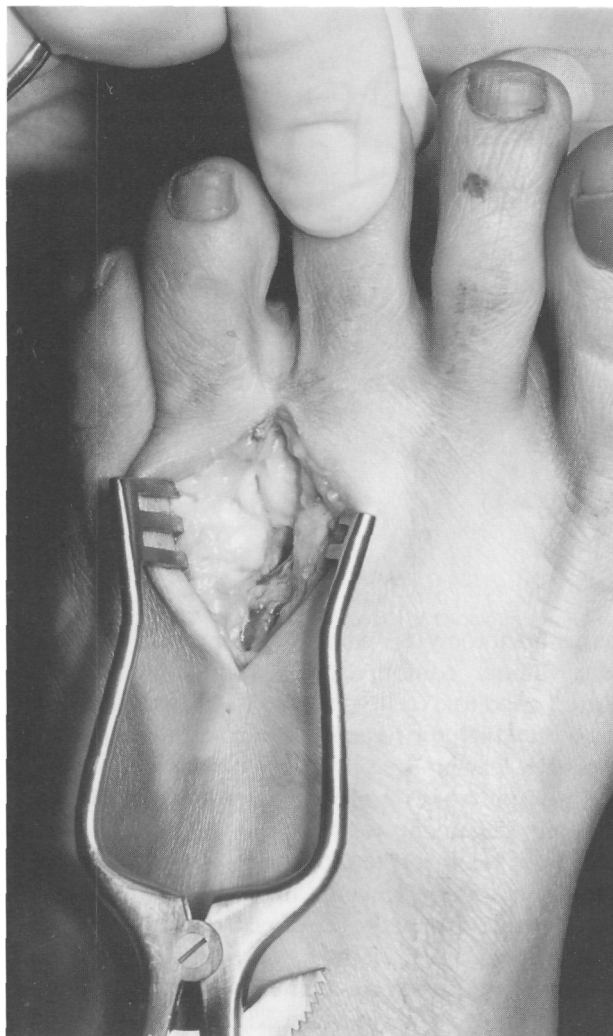


Fig. 28-25. Dissection for dorsal excision of Morton's neuroma.

deformities. When a single incision is utilized, it is necessary to ensure dissection is carried down to a level below the subcutaneous tissue that contains the vascular structures before undermining into either intermetatarsal space. When circulation is identified as marginal, the more painful neuroma should be excised first and the adjacent intermetatarsal neuroma resected 1 to 2 months after the primary incision has healed.⁷

Surgical Complications

Whatever approach is made for intermetatarsal neuroma surgery, observance of several principles will minimize complications.⁷ These include the following:

1. Gentle handling of tissues at all times.
2. Meticulous hemostasis. A cuff or tourniquet is not necessary.
3. Identification of the digital branches before completing the resection.
4. Removal of the neuroma without damaging the intermetatarsal artery or the local tendon from the lumbrical muscle.
5. Clean transection of the nerve trunk far enough proximally to prevent irritation or adhesions to the stump.
6. Intraneural injection of the proximal nerve trunk before transection, with one or two drops of steroid solution to impede scar adhesions and sensitive axon sprouts at the nerve end.

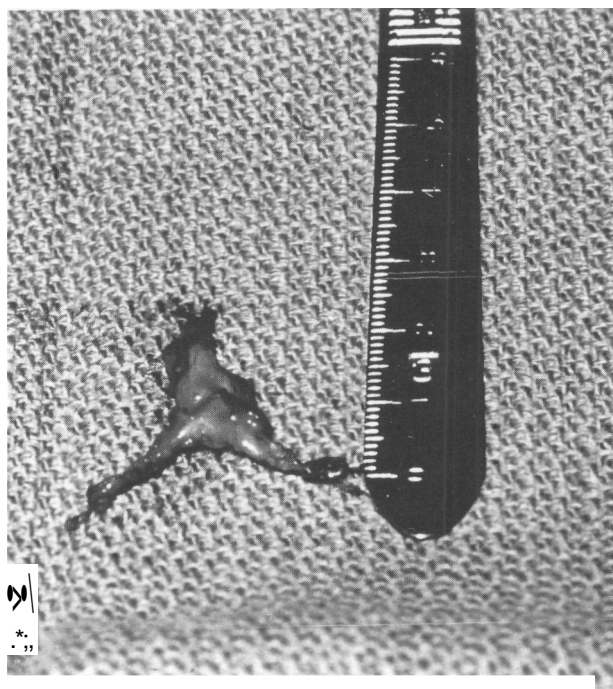


Fig. 28-26. Gross neuroma specimen exhibiting digital branches.

7. Closure of dead space as necessary. When this is not possible a closed suction drain should be inserted.
8. Use of a firm, even compression dressing, which is essential to help prevent postoperative hematoma formation.

Hematoma can form in the dead space following a neuroma resection as a result of blood and serum accumulation. Not only will this intensely prolong the initial inflammatory phase of healing, with added pain and frustration, but it is also an excellent medium for bacteria proliferation. Prophylactic antibiotics, expression of the hematoma, compression dressings, needle aspiration, and surgical removal of the clot are approaches to treatment.

Vascular ischemia of the toes results from interruption of arterial supply, vasospasm, and congestion from postoperative edema. Early recognition should lead to prompt treatment including the following: loosening of any tight dressings, removal of ice, reflex heat, sympathetic nerve blocks, reversal of epinephrine effects using local infiltration with phentolamine (Regitine), abstinence from caffeine and nicotine, and warming up the surrounding environment. In emergency situations, 5 to 10 mg of isoxuprine (Vasodilan) intramuscularly or 10 mg of nifedipine (Procardia) orally should stimulate effective vasodilation. Unchecked, a cyanotic toe can progress to frank gangrene with subsequent amputation.

The most troublesome complication probably is the painful *stump neuroma* or *recurrent neuroma* formation. Actually, a true bulbous stump neuroma is a rare finding at secondary operation. In most instances, recurrent neuromas presented with adhesions to the plantar joint capsule of a metatarsal head; the pain appeared to be the result of traction/impingement forces causing mechanosensitivity at the transected nerve ending.^{83,115} The same authors⁸³ identified, in one-third of their reoperated cases, an accessory nerve trunk passing under the deep transverse intermetatarsal ligament. It appeared to have developed into a "recurrent neuroma," having been damaged at the time of the primary surgery.⁶⁹

Recurrent neuroma is identified by sharp, often lancinating, or burning paresthesia aggravated by weight-bearing or point pressure and persisting well after

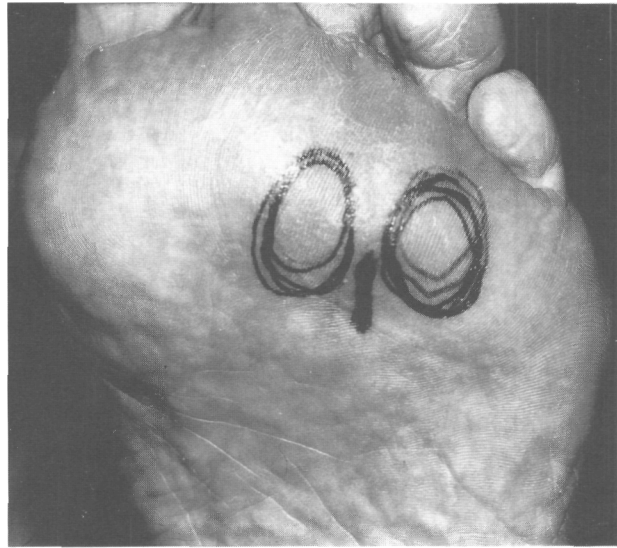


Fig. 28-27. Usual point of maximum tenderness following excision of Morton's neuroma.

local tissues have healed (Fig. 28-27). Symptoms can even be similar to those experienced before the initial surgery. Treatment is initially conservative using various padding and injection techniques. Triamcinolone acetonide infiltration is thought to soften the scar tissue adhering the nerve end to surrounding tissue, thus providing a measure of release.¹¹⁶

Surgical reentry must be via a plantar incision to provide good visualization plus access to the more proximal nerve trunks (Fig. 28-28). The goal is neurolysis to free the nerve plus a clean transection of the nerve more proximally with the nerve under tension. The end should then withdraw into the intrinsic muscle bellies away from weight-bearing areas for protection. Implementation of several prophylactic measures will help minimize further adhesions or stump neuroma formations. Intraneural steroid injection, 4 percent alcohol sclerosing solution, and a metal ligation clamp help discourage neurite formation/Containment of the axon sprouts and protection against adhesions is the goal of silicone caps, which can be applied to the end of the nerve to isolate it.¹¹⁷⁻¹¹⁹ Unfortunately, there are no good controlled studies to examine the efficacy of such treatment.

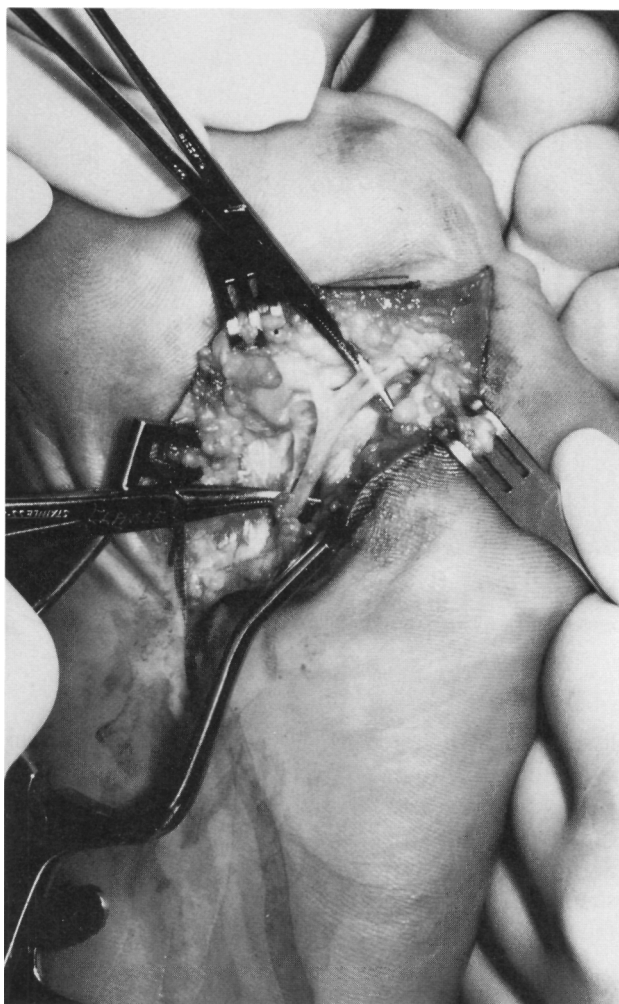


Fig. 28-28. Adherence of nerve stump to adjacent metatarsal head capsular tissue as seen on reentry (plantar approach).

Results of reoperation for intermetatarsal neuromas vary widely. Bradley and associates⁸¹ found unsatisfactory results in four of five patients reexplored while Mann and Reynolds⁸³ reported significant improvement in nine of eleven patients (81 percent), and Beskin and Baxter¹²⁰ achieved 50 percent or greater improvement in 33 of 38 patients (87 percent). Nelms et al.¹²¹ were able to obtain good to excellent results in 24 of 27 patients (89 percent) by tucking the nerve end into a drill hole in an adjacent metatarsal.

Results of Surgery

Several studies have shown that satisfactory results occur in an average of 84 percent of the patients who undergo neurectomy surgery^{81-84,122} (Table 28-8). A good portion of these will still have some uncomfortable yet tolerable sensations lingering. Results are better when the third intermetatarsal space alone is involved and decrease dramatically when it is dissected bilaterally or when the second or others are involved.^{84,122}

Beskin and Baxter¹²⁰ identified two clinical groups of patients who experience pain following neurectomy: those that remain symptomatic after neurectomy and those that recur after a period of quiescence. Identifying patients preoperatively who are at risk for recurrent neuroma formation is virtually impossible, although it is a goal worthy of pursuing.

Actually, what remains after neurectomy is a severed nerve, the same as when a limb is amputated. Spontaneous firing starts the day the nerve is cut and has two peaks of activity: the first occurs at about the third day and the second occurs within the third week.¹²³ For some people this is a much more sensitive phenomenon than for others, perhaps moderated or enhanced by neighboring sympathetic fibers.^{124,125} Ectopic neural discharge can be suppressed by intraneural injection of corticosteroid preparations before severance of the nerve.¹²⁶

As the end of the nerve degenerates, immature axon "sprouts" form. These can be quite sensitive, especially to mechanical pressure. The axons will extrude with unlimited growth potential seeking to connect with the distal axons. When blocked by local tissues or scar, the axons can convolute into a painful stump

Table 28-8. Unsatisfactory Results of Neuroma Surgery

Study	Percentage
Bradley et al. (1976) ⁸⁶	13 (34.3)
Gauthier (1979) ⁸²	17
Mann and Reynolds (1983) ⁸³	20
Gudas and Mattana (1986) ⁸⁴	21
Karges (1988) ¹¹⁴	7
Johnson (1989) ¹²²	19
Average	16

neuroma. Simultaneously, the fibroblasts within the supporting perineurium and epineurium are forming scar tissue that can bind down the end of the nerve and place it under traction tension or compression.

In conclusion, excision of the intermetatarsal neuroma is a procedure not to be undertaken without a thorough patient workup and meticulous surgical technique. Honest patient rapport and responsible postoperative management will lead to a cooperative relationship when complications arise.

REFERENCES

1. Dyck PJ: The causes, classification and treatment of peripheral neuropathy. *New Engl J Med*, 307:283, 1982
2. McQuarrie IG: Peripheral nerve surgery—today and looking ahead. *Clin Plast Surg* 13:255, 1986
3. Fisher GT, Boswick JA: Neuroma formation following digital amputations. *J Trauma* 23:136, 1983
4. Matthews GJ, Osterholm JL: Painful traumatic neuromas. *Surg Clin N Am* 51:1313, 1972
5. Durlacher L: A Treatise on Corns, Bunions, the Diseases of Nails and the General Management of the Feet, p. 52. Simkin, Marshall, London, 1845
6. Miller SJ: Surgical technique for resection of Morton's neuroma. *J Am Podiatry Assoc* 71:181, 1981
7. Miller SJ: Morton's neuroma: a syndrome, p. 38. In McGlamry ED, McGlamry R (eds): *Textbook on Foot Surgery*, Vol. 1. Williams & Wilkins, Baltimore, 1987
8. Kravette MA: Peripheral nerve entrapment syndromes in the foot. *J Am Podiatry Assoc* 61:457, 1971
9. Sarrafian SK: *Anatomy of the Foot and Ankle: Descriptive, Topographic and Functional*, p. 317. JB Lippincott, Philadelphia, 1983
10. Millesi H, Terzis J: Nomenclature in peripheral nerve surgery. Committee report of the International Society of Reconstructive Microsurgery. *Clin Plast Surg* 11:3, 1984
11. Battista AF, Lusskin R: The anatomy and physiology of the peripheral nerve. *Foot Ankle* 7:65, 1986
12. Pollock LJ, Davis L: *Peripheral Nerve Injuries*, p. 484. Hoeber, New York, 1933
13. Keck C: The tarsal tunnel syndrome. *J Bone Joint Surg Am* 44:180, 1962
14. Lam SJS: The tarsal tunnel syndrome. *J Bone Joint Surg Br* 49:87, 1967
15. Edwards WG, Lincoln CR, Bassett FII, Goldner JL: The tarsal tunnel syndrome: diagnosis and treatment. *JAMA* 207:716, 1969
16. Havens RT, Kaloogian H, Thul JR, Hoffman S: A correlation between os trigonum syndrome and tarsal tunnel syndrome. *J Am Podiatr Med Assoc* 76:450, 1986
17. Goodman CR, Kehr LE: Bilateral tarsal tunnel syndrome: a correlative perspective. *J Am Podiatr Med Assoc* 78:292, 1988
18. Radin EL: Tarsal tunnel syndrome. *Clin Orthop Relat Res* 181:167, 1983
19. Mann RA: Tarsal tunnel syndrome. *Orthop Clin N Am* 5:109, 1974
20. Johnson EW, Ortiz PR: Electrodiagnosis of tarsal tunnel syndrome. *Arch Phys Med* 45:548, 1964
21. Gilliat RW, Wilson TG: A pneumatic tourniquet test in carpal tunnel syndrome. *Lancet* 2:595, 1953
22. Malay DS, McGlamry ED, Nava CA Jr: Entrapment neuropathies of the lower extremities. In *Textbook on Foot Surgery*, Vol. II, p. 668. Williams & Wilkins, Baltimore, 1987
23. Dellon AL, MacKinnon SE: Tibial nerve branching in the tarsal tunnel. *Arch Neurol* 41:645, 1984
24. Przylucki H, Jones CL: Entrapment neuropathy of muscle branch of lateral plantar nerve: a cause of heel pain. *J Am Podiatry Assoc* 71:119, 1981
25. Henricson AS, Westlin NE: Chronic calcaneal pain in athletes: entrapment of the calcaneal nerve. *Am J Sports Med* 12:152, 1984
26. Baxter DE, Thigpen CM: Heel pain—operative results. *Foot Ankle* 5:16, 1984
27. Havel PE, Ebraheim NA, Clark SE, Jackson WT, DiDio L: Tibial branching in the tarsal tunnel. *Foot Ankle* 9:117, 1988
28. Kopel HP, Thompson AL: Peripheral entrapment neuropathy of the lower extremity. *N Engl J Med* 262:56, 1960
29. Rask ME: Medial plantar neuroparaxia (jogger's foot): report of three cases. *Clin Orthop* 154:193, 1978
30. Kenzora JE: Symptomatic incisional neuromas on the dorsum of the foot. *Foot Ankle* 5:2, 1984
31. Dockery GL, Nilson RV: Intralesional injections. *Clin Podiatr Med Surg* 3:473, 1986
32. Edwards WG, Lincoln CR, Bassett FH, Goldner JL: The tarsal tunnel syndrome: diagnosis and treatment. *JAMA* 207:716, 1969
33. Kenzora JE: Sensory nerve neuromas—leading to failed foot surgery. *Foot Ankle* 7:110, 1986
34. Meals RA: Peroneal nerve palsy complicating ankle sprain. *J Bone Joint Surg Am* 59:966, 1977
35. Vasamaki M: Decompression for peroneal nerve entrapment. *Acta Orthop Scand* 57:551, 1986

36. Lemont H, Hernandez A: Recalcitrant pain syndromes of the foot and ankle: evaluation of the lateral dorsal cutaneous nerve. *J Am Podiatry Assoc* 62:331, 1972
37. Krause KH, Witt T, Ross A: Anterior tarsal tunnel syndrome. *J Neurol* 217:67, 1977
38. Borges LF, Hallett M, Selkoe DJ, Welch K: The anterior tarsal tunnel syndrome. Report of two cases. *J Neurosurg* 54:89, 1981
39. Gessini L, Jandolo B, Pietrangeli A: The anterior tarsal syndrome: Report of four cases. *J Bone Joint Surg Am* 66:786, 1984
40. Adelman KA, Wilson G, Wolf JA: Anterior tarsal tunnel syndrome. *J Foot Surg* 27:299, 1988
41. Dellon AL: Deep peroneal nerve entrapment on the dorsum of the foot. *Foot Ankle* 11:73, 1990
42. Joplin RJ: The proper digital nerve, vitallium stem arthroplasty, and some thoughts about foot surgery in general. *Clin Orthop Relat Res* 76:199, 1971
43. Merritt GN, Subotnick SI: Medial plantar digital proper nerve syndrome (Joplin's neuroma): typical presentation. *J Foot Surg* 21:166, 1982
44. Lee B, Crowhurst JA: Entrapment neuropathy of the first metatarsophalangeal joint: two case reports. *J Am Podiatr Med Assoc* 77:657, 1987
45. Thul JR, Hoffman SJ: Neuromas associated with tailor's bunions. *J Foot Surg* 24:342, 1985
46. Addante JB, Peicott PS, Wong KY, Brooks DL: Interdigital neuromas: results of surgical excision of 152 neuromas. *J Am Podiatric Med Assoc*, 76:493, 1986
47. Reed RJ, Bliss BO: Morton's neuroma: Regressive and productive intermetatarsal elastofibrosis. *Arch Pathol*, 95:123, 1973
48. Sheperd E: Intermetatarsophalangeal bursitis in the causation of Morton's metatarsalgia. *J Bone Joint Surg Br* 57:115, 1975
49. Bossley CJ, Cairney PC: The metatarsophalangeal bursa—its significance in Morton's metatarsalgia. *J Bone Joint Surg Br* 62:184, 1980
50. Burns AE, Stewart WP: Morton's neuroma. *J Am Podiatry Assoc* 72:135, 1982
51. Goldman F, Gardner R: Pacinian corpuscles as a cause for metatarsalgia. *J Am Podiatry Assoc* 70:561, 1980
52. Ochoa J: The primary nerve fibre pathology of plantar neuromas. *J Neuropathol Exp Neurol* 35:370, 1976
53. Goldman F: Intermetatarsal neuroma: Light microscopic observations. *J Am Podiatry Assoc* 69:317, 1979
54. King LS: Note on the pathology of Morton's metatarsalgia. *Am J Clin Pathol* 16:124, 1946
55. Nissen KI: Plantar digital neuritis. *J Bone Joint Surg Br* 30:84, 1948
56. Scott TM: The lesion of Morton's metatarsalgia (Morton's toe). *Arch Pathol* 63:91, 1957
57. Lassmann G, Machacek J: Clinical features and histology of Morton's metatarsalgia. *Wien Klin Wochenschr* 81:55, 1969
58. Meachim G, Aberton JJ: Histological findings in Morton's metatarsalgia. *J Pathol* 103:209, 1971
59. Lassmann G, Lassmann H, Stockinger L: Morton's metatarsalgia. Light and electron microscopic observations and their relation to entrapment neuropathies. *Virchows Arch Pathol Anat* 370:307, 1976
60. Lassmann G: Morton's toe: clinical, light, and electron microscopic investigations in 133 cases. *Clin Orthop* 142:73, 1979
61. Goldman F: Intermetatarsal neuromas—light and electron microscopic observations. *J Am Podiatry Assoc* 70:265, 1980
62. Ringertz N, Unander-Scharin ML: Morton's disease: a clinical and patho-anatomical study. *Acta Orthop Scand* 19:327, 1950
63. Guiloff RJ, Scadding JW, Klenerman L: Morton's metatarsalgia: clinical, electrophysiological, and histological observations. *J Bone Joint Surg Br* 66:586, 1984
64. Graham CE, Graham DM: Morton's neuromas: a microscopic evaluation. *Foot Ankle* 5:150, 1984
65. Tate RO, Rusin JJ: Morton's neuroma: its ultrastructural anatomy and biomechanical etiology. *J Am Podiatry Assoc* 68:797, 1978
66. Baker LD, Kuhn MH: Morton's metatarsalgia: localized degenerative fibrosis with neuromatous proliferation of the fourth plantar nerve. *South Med J* 37:123, 1944
67. Hauser EDW: Neurofibroma of the foot. *JAMA* 121:1217, 1943
68. Viladot A, Moragas A: Entermedad de Morton. *Podologica* 5:233, 1966
69. Alexander IJ, Johnson KA, Parr JW: Morton's neuroma: a review of recent concepts. *Orthopedics* 10:103, 1987
70. Gilbey VP: The non-operative treatment of metatarsalgia. *J New Ment Health Dis* 19:589, 1894
71. Pincus A: Intractable Morton's toe (neuroma). Review of the literature and report of cases. *J Am Podiatry Assoc* 40:19, 1950
72. Bartolomei FJ, Wertheimer SJ: Intermetatarsal neuromas: distribution and etiologic factors. *J Foot Surg* 22:279, 1983
73. Carrier PA, et al: Morton's neuroma: a possible contributing etiology. *J Am Podiatry Assoc* 65:315, 1975
74. Sgarlato TE: Compendium of Podiatric Biomechanics. California College of Podiatric Medicine, San Francisco, 1971
75. Root ML, Orien WF, Weed JM: Normal and abnormal function of the foot. In *Clinical Biomechanics*, Vol. 2, pp. 112, 296, 322. Clinical Biomechanics Corp., Los Angeles, 1977

76. Bickel VH, Dockerty MB: Plantar neuromas, Morton's toe. *Surg Gynecol Obstet* 84:111, 1947
77. Belts LO: Morton's metatarsalgia. *Med J Aust* 1:514, 1940
78. McElvenny RT: The etiology and surgical treatment of intractable pain about the fourth metatarsophalangeal joint (Morton's toe). *J Bone Joint Surg* 25:675, 1943
79. Denny-Brown D, Doherty MM: Effects of transient stretching of peripheral nerve. *Arch Neurol Psychol* 54:116, 1945
80. Wachter S, Nilson RZ, Thul JR: The relationship between foot structure and intermetatarsal neuromas. *J Foot Surg* 23:436, 1984
81. Bradley N, Miller WA, Evans JP: Plantar neuroma: analysis of results following surgical excision in 145 patients. *South Med J* 69:853, 1976
82. Gauthier G: Thomas Morton's disease: a nerve entrapment syndrome. A new surgical technique. *Clin Orthop Relat Res* 142:90, 1979
83. Mann RA, Reynolds JC: Interdigital neuroma—a critical analysis. *Foot Ankle* 3:248, 1983
84. Gudas CJ, Mattana GM: Retrospective analysis of intermetatarsal neuroma excision with preservation of the transverse metatarsal ligament. *J Foot Surg*, 25:459, 1986
85. Addante JB, Peicott PS, Wong KY, Broods DL: Interdigital neuromas: results of surgical excision of 152 neuromas. *J Am Podiatry Assoc* 52:746, 1962
86. Pincus A: The syndrome of plantar metatarsal neuritis. *J Am Podiatry Assoc* 52:746, 1962
87. Mulder JD: The causative mechanism in Morton's metatarsalgia. *J Bone Joint Surg* 33B:94, 1951
88. Berlin SJ, Donick I, Block LD, Costa AL: Nerve tumors of the foot: diagnosis and treatment. *J Am Podiatry Assoc* 65:157, 1975
89. Oh SJ, Kim HS, Ahmed BK: Electrophysiological diagnosis of interdigital neuropathy of the foot. *Muscle Nerve* 7:218, 1984
90. Sartoris DJ, Brozinsky S, Resnick D: Magnetic resonance images. *J Foot Surg* 28:78, 1989
91. Redd PA, Peters VJ, Emery SP, Bunch HM, Rifkin MD: Morton neuroma: sonographic evaluation. *Radiology* 171:415, 1989
92. Schreiber LJ: Method of padding for Morton's neuralgia. *J Am Podiatry Assoc* 29:5, 1939
93. Polokoff MM: The treatment of Morton's metatarsalgia. *J Am Podiatry Assoc* 38:27, 1948
94. Brohner MD: Morton's toe or Morton's neuralgia. *J Am Podiatry Assoc* 39(3):18, 1949
95. Silvermann LJ: Old principles and new ideas. *J Am Podiatry Assoc* 31:7, 1941
96. Milgram JE: Morton's neuritis and management of post-neurectomy pain. p. 203. In Omer GE, Spinner M (eds): *Management of Peripheral Nerve Problems*. WB Saunders, Philadelphia, 1980
97. Milgram JE: Office methods for the relief of the painful foot. *J Bone Joint Surg Am* 49:1099, 1964
98. Withman R: Anterior metatarsalgia. *Trans Am Orthop Assoc* 11:34, 1898
99. Hohmann G: Über die Mortonsche neuralgie am fuss Bietrage. *Orthopade* 13:649, 1966
100. Silverman LJ: Morton's toe or Morton's neuralgia. *J Am Podiatry Assoc* 66:749, 1976
101. Milgram JE: Design and use of pads and strappings for office relief of the painful foot. p. 95. In Kiene RH, Johnson KA (eds): *Symposium on the Foot and Ankle*. CV Mosby, St. Louis, 1983
102. Steinberg MD: The use of vitamin B-12 in Morton's neuralgia. *J Am Podiatry Assoc* 45:41, 1955
103. Wright EW: Injection therapy in Morton's neuralgia. *J Am Podiatry Assoc* 45:566, 1955
104. Cozen L: Neuroma of plantar digital nerve, p. 224. In *Clinical Orthopedics*, Vol. 2. JB Lippincott, Philadelphia, 1958
105. Greenfield J, Rea J, Ilfeld FW: Morton's interdigital neuroma: indications for treatment by local injections versus surgery. *Clin Orthop Relat Res* 185:142, 1985
106. Lapidus PW, Wilson MJ: Morton's metatarsalgia. *Bull NY Med Coll* 12:34, 1969
107. Giannestras NJ: *Foot Disorders, Medical and Surgical Management*, p. 494. Lea & Febiger, Philadelphia, 1967
108. May VR Jr: The enigma of Morton's neuroma, p. 222. In Bateman JE (ed.) *Foot Science*. WB Saunders, Philadelphia, 1976
109. Joplin RJ: Some common foot disorders amenable to surgery. *AAOS Instructional Course Lectures* 15:144, 1958
110. Kelikian H: Hallux Valgus, Allied Deformities of the Forefoot, Metatarsalgia, p. 359. WB Saunders, Philadelphia, 1965
111. Kaplan EB: Surgical approach to the plantar digital nerves. *Bull Hosp Joint Dis Orthop Inst*, 1:96, 1950
112. McKeever DC: Surgical approach for neuroma of plantar digital nerve (Morton's metatarsalgia). *J Bone Joint Surg* 34A:490, 1952
113. Kitting RW, McGlamry ED: Removal of an intermetatarsal neuroma. *J Am Podiatry Assoc* 63:274, 1973
114. Karges DE: Plantar excision of primary interdigital neuromas. *Foot Ankle* 9:120, 1988
115. Nelms BA, Bishop JO, Tullos HS: Surgical treatment of recurrent Morton's neuroma. *Orthopedics* 7:1708, 1984

116. Smith JR, Gomez NH: Local injection therapy of neuromata of the hand with triamcinalone acetonide. *J Bone Joint Surg* 52:71, 1970
117. Swanson AB, Boeve NR, Lumsden RM: The prevention and treatment of amputation neuromata by silicone capping. *J Hand Surg* 2:70, 1977
118. Burke BR: A preliminary report in the use of silastic nerve caps in conjunction with neuroma surgery. *J Foot Surg* 17:53, 1978
119. Midenberg ML, Kirshcenbaum SE: Utilization of silastic nerve caps in conjunction with neuroma surgery. *J Foot Surg* 17:53, 1978
120. Beskin JL, Baxter DE: Recurrent pain following interdigital neurectomy—a plantar approach. *Foot Ankle* 9:34, 1988
121. Nelms BA, Bishop JO, Tullos HS: Surgical treatment of recurrent Morton's neuroma. *Orthopedics* 7:1708, 1984
122. Johnson KA: *Surgery of the Foot and Ankle*, p. 69. Raven Press, New York, 1989
123. Scadding JW: Development of ongoing activity, mechanosensitivity, and adrenaline sensitivity in severed peripheral nerve axons. *Exp Neurol* 73:345, 1981
124. Devor M, Janig W: Activation of myelinated afferents ending in a neuroma by stimulation of the sympathetic supply in the rat. *Neurosci Lett* 24:43, 1981
125. Wall PD, Gutnick M: Ongoing activity in peripheral nerves: the physiology and pharmacology of impulses originating from a neuroma. *Exp Neurol* 43:580, 1974
126. Devor M, Govrin-Lippmann R, Raber P: Corticosteroids suppress ectopic neural discharge originating in experimental neuromas. *Pain* 22:127, 1985