27

Orthodigital Evaluation and Therapeutic Management of Digital Deformity

KENDRICK A. WHITNEY

The definition of orthodigita might imply a conservative nonoperative approach to the correction and control of digital malalignments and associated lesions. A better concept, however, might include the combined orthopedic and judicious surgical management of digital deformities where indicated. The decision as to which approach, whether conservative, surgical, or combined, would be most beneficial for the patient should be based on clear principles and findings. It is paramount that the examination determines the precise type, degree, and reducibility of a presented deformity. The most important and perhaps most often overlooked factors are the various orthopedic influences that may contribute directly or indirectly to the development of the digital deformity and which will most certainly help determine the most appropriate type of treatment.

Before selecting and performing any digital procedure, it is essential that the practitioner have an appreciable understanding of the presenting problem or complaint. The nature and developmental sequence of the digital deformity must be ascertained through a careful and thorough history and physical examination. Only then should the practitioner proceed with a specific treatment plan based on clear and sound principles rather than on financial gain, technical ease, or short-term cosmetic results, further, it is generally not only the severity of the deformation that should determine the therapeutic procedure to be performed. In most cases, the success of treatment will depend greatly on the recognition and classification of the relative resistance to manual corrective digital realignment. It is thus the author's hope that a systematic approach to the evaluation and treatment of digital deformities may help to deter some of the indiscriminate digital surgery leading to long-term disfigurement and dysfunctional results.

ORTHODIGIAL EVALUATION PROCEDURE

Patient History

A detailed patient narrative should be taken, which may often provide valuable insight to an overall understanding of the nature and developmental sequence of the presented digital problem. Previous treatments received and the negative or positive results obtained may yield clues as to the best therapeutic direction. This becomes increasingly important when the treatment received was related to a secondary orthopedic complaint. Certainly the functional demands imposed by the patient's vocational and avocational needs will also play a significant role in the treatment program selected.

The limiting factor to successful orthodigital management is, very often, the patient's shoe gear. It is extremely important to ascertain whether the patient's shoe style has contributed to the progression or worsening of the problem. Foot abuse from improper shoe

style with respect to the last, toe box room, and the heel height are significant contributors to digital malposition and associated lesions that must not be taken lightly. Careful shoe inspection and patient education with respect to a favorable shoe type for the digital condition can make the difference between failure and successful orthodigital management.

The past medical history should include a clear understanding of the patient's current health with an emphasis on circulation, injuries, operations, and allergies in terms of potential digital surgery needs.

Overall Evaluation

The orthodigital exam should be considered a vital portion of the generalized lower extremity exam as the two are inevitably linked. The examiner should refrain from immediately addressing the digital complaint (often to the patient's chagrin) while an overall perception is formed as to the nature of the digital complaint and its probable development. This lower extremity preorthodigital evaluation should allow the practitioner to distinguish between the purely positional, chronically adapted, and structural congenital digital deformity.

Visual Evaluation

With the patient comfortably seated and the knees placed in a slightly flexed attitude the examiner should observe the foot and toes in the relaxed state, noting both the location and plane of deformity while also observing skin tensions, lesional characteristics, tendinous contractures, and joint abnormalities that may be present (Fig. 27-1).

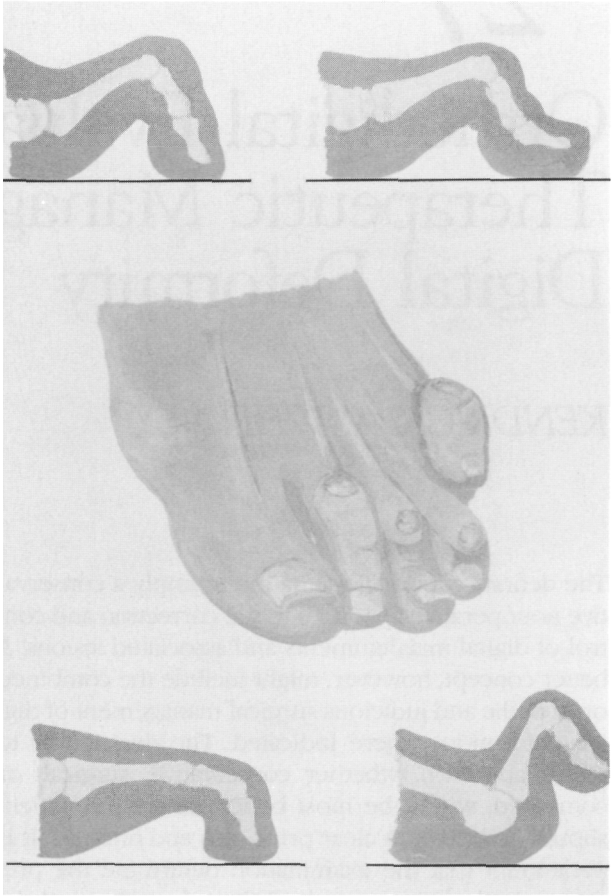

Fig. 27-1. Visual foot and digital evaluation.

Manual Evaluation

Following the visual inspection a manual appraisal will help further determine the nature, extent, and therapeutic prognosis of the digital deformity while palpable pain and associated arthritic changes are noted. Passive and active range of motion (ROM) and muscle testing should be performed on all digits (Fig. 27-2). Metatarsophalangeal malalignments are specifically charted with reference to their degree, taxicity, subluxation, or frank luxation (Fig. 27-3). A simple test used to determine subluxation potential at the metatarsophalangeal joint level involves the application of resistance over the distal aspect of the toe by the examiner while the patient actively extends the digits (Fig. 27-4). If a subluxation tendency exists, the proximal phalangeal base can be observed to sublux proximally over its metatarsal head.

FUNCTIONAL ORTHODIGITAL EVALUATION

Taxicity Testing

To help the examiner determine the taxic (reducible) from the nontaxic digital elements, the author has de-

Fig. 27-2. Resistive testing of the extensor digitorum brevis muscle.

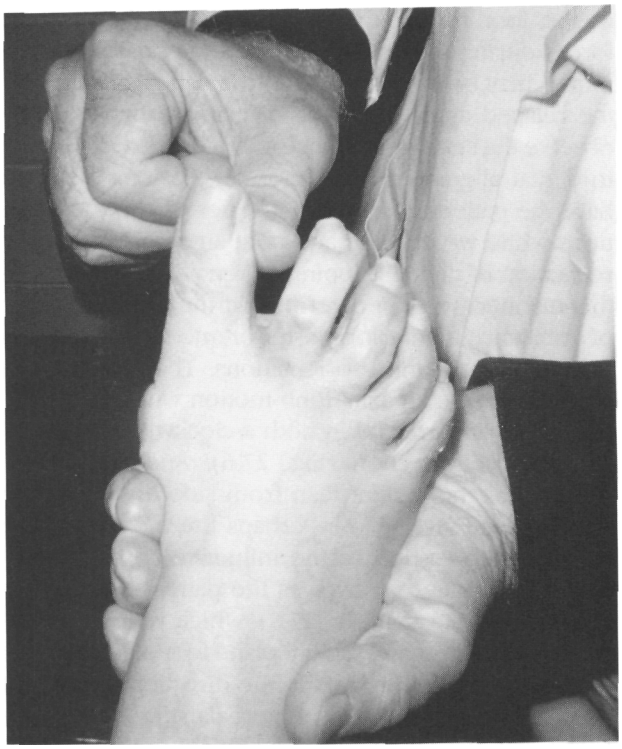

Fig. 27-3. Passive hallux motion and resistance testing.

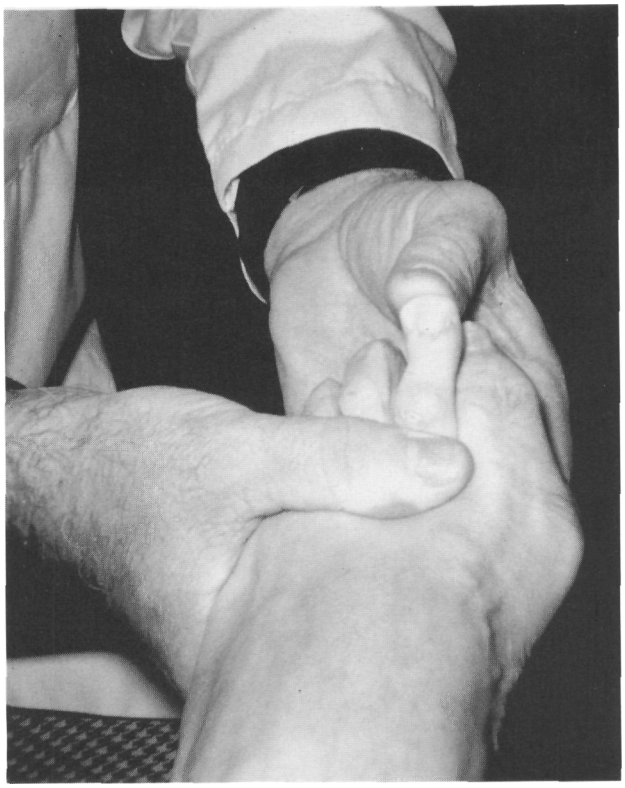

Fig. 27-4. Testing metatarsophalangeal joint subluxation potential.

vised a taxicity resistance scale (Table 27-1) in which the resistance to manual reduction of digital deformity is measured on a scale of 1 to 5. This test procedure, which measures the ease of digital realignment by the practitioner, is performed with the patient both sitting and standing. The information derived from this test is utilized for determining the most appropriate therapeutic measures and probable prognosis. Lesser digital deformities, which have taxicity resistance values

Table 27-1. Taxicitv Resistance Scale

	At Rest	During Stance
1(+)	Easily reducible	Reducible
2(++)	Reducible	Mild resistance
3(+++)	Mild resistance	Moderate resistance
4(++++)	Moderate resistance	Incomplete reduction
5(+++++)	Nonreducible	Nonreducible

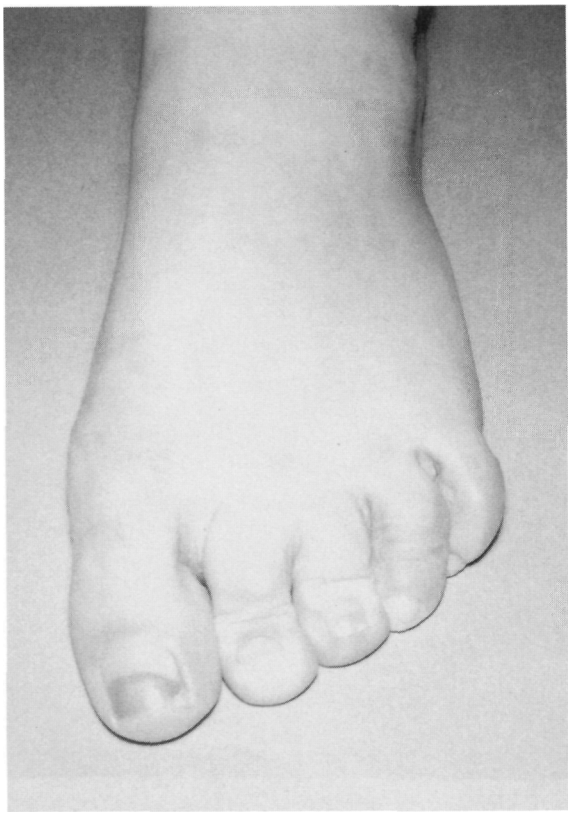

Fig. 27-5. Digital gripping response to compensate forefoot varus deformity.

between 1 and 3 and are secondary to functional imbalance rather than tendinous malinsertion or progressive neurologic deformities, will generally respond favorably to aggressive conservative orthodigital therapy. Deformities falling within a 3 to 4 taxic resistance range while still manually reducible will generally require some type of soft tissue release or osseous surgical procedure in conjunction with retentive orthodigital measures to prevent recurrence. Grade 5 nontaxic deformities are totally nonreducible and will require either surgical reconstructive techniques or protective orthodigital shielding.

Positional Digital Malalignment

Digital deformities generally representing the lower end of the taxicity resistance scale display the easiest manual reduction and are usually secondary to an underlying foot defect whereby the digits will grip or claw to compensate or counterbalance the underlying deficiency (Fig. 27-5). These easily reducible deformities will generally respond well to conservative orthopedic measures via mechanical accommodation. Other orthopedic influences that may contribute to these functional digital patterns include the patient's occupational and avocational demands, weight, posture, gait patterns, foot gear, and general health. Without an appreciation or clear understanding of the underlying foot-limb imbalance responsible for these digital deformities, surgical intervention will inevitably produce greater long-term problems than the initial presenting complaint. The role of the practitioner should then be to determine which of these functional/orthopedic influences may be contributing to the presenting digital malalignment and then to act on those influences.

Sway Balance Testing

To help determine the nature and source of imbalance in the foot responsible for the digital deformation forces during stance and gait, the sway balance technique[1] may be employed. With the patient standing in the relaxed angle and base of gait, we first need to observe the static appearance of the digits with respect to digital alignment and abnormal tensions. Next we have the patient go through a series of specified motions while we observe and note any accentuation or relaxation of digital gripping or retraction patterns. In this manner one can determine if the foot/leg vector of imbalance is anterior, posterior, medial, lateral, or a combination of these orientations. The motions described include an axial limb motion wherein the patient's pelvis is rotated in both a clockwise and counterclockwise direction (Fig. 27-6). Another motion pattern has the patient lean from side to side in the frontal plane (Fig. 27-7). Perhaps the most revealing motion, with respect to the influence on compensatory digital patterns, involves the patient leaning forward and backward (Fig. 27-8), which reflects the influence of underlying sagittal plane foot defects on the toes. As the patient moves in the direction of the foot imbalance, the digital counterbalancing is exacerbated, revealing the nature and extent of the underlying foot imbalance. The practitioner may then attempt

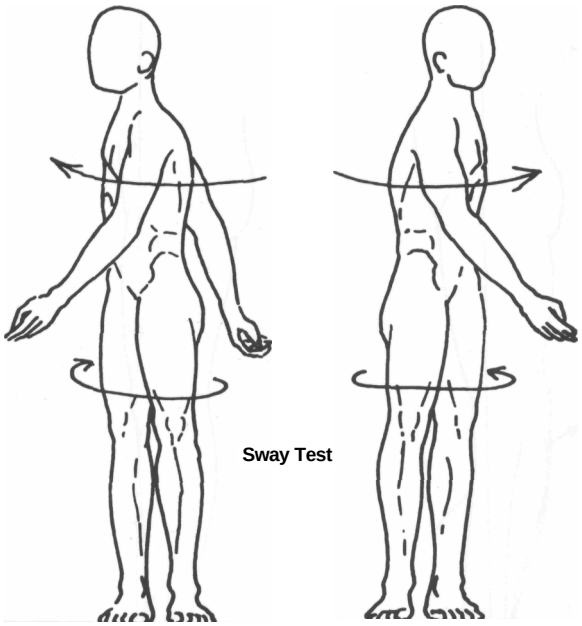

Fig. 27-6. Sway rotation testing.

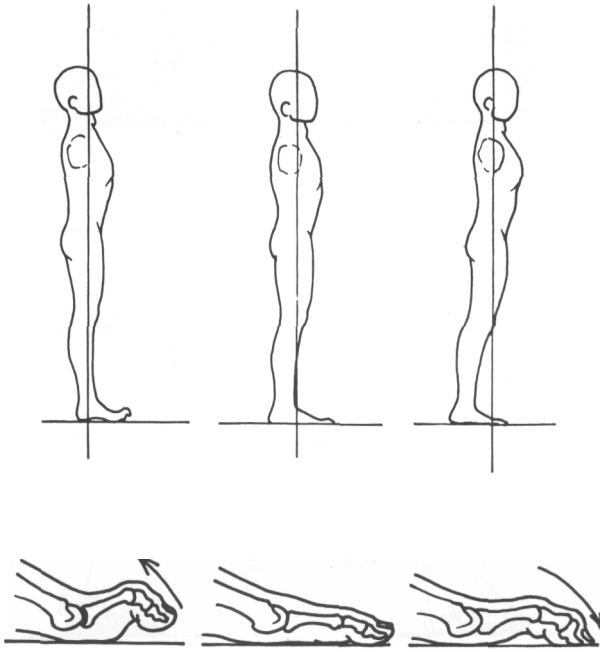

Fig. 27-8. Digital response to front-to-back sway testing.

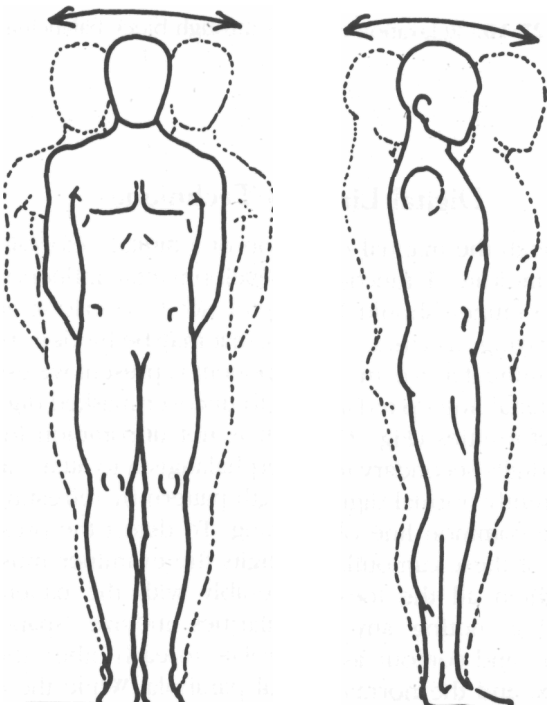

Fig. 27-7. Side-to-side and front-to-back sway testing.

corrective test rebalance of the suspected foot defect with test blocks or wedges.

Block Balance Technique

After the suspected area of foot insufficiency has been identified, blocks and wedges of a semirigid nature are placed under that area or region to neutralize the situation (Fig. 27-9).[2] When the appropriate block or wedge has been selected, the digits should attain a more relaxed normal alignment attitude (Fig. 27-10). The extent of corrective digital reduction usually depend on the degree of functional involvement and chronicity of deformity. When the deformity is purely positional in nature and no adaptive changes have taken place, complete correction is often achieved with functional foot rebalance utilizing initial test balance pad therapy[3] followed by orthosis control. In situations in which adaptive digital changes have already occurred and that demonstrate a moderate to high taxicity resistance grading, a more aggressive orthodigital approach and a surgical solution may be required.

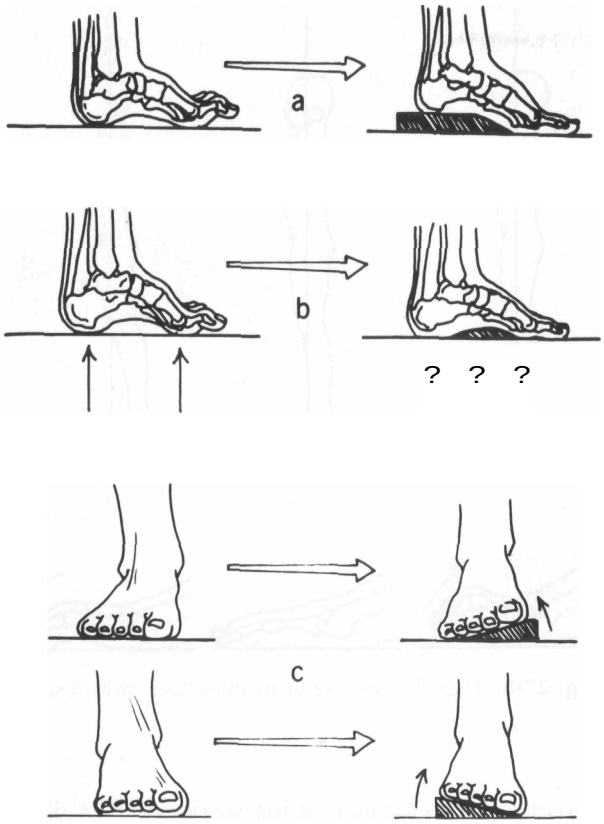

Fig. 27-9. (A-C) Block balance Testing.

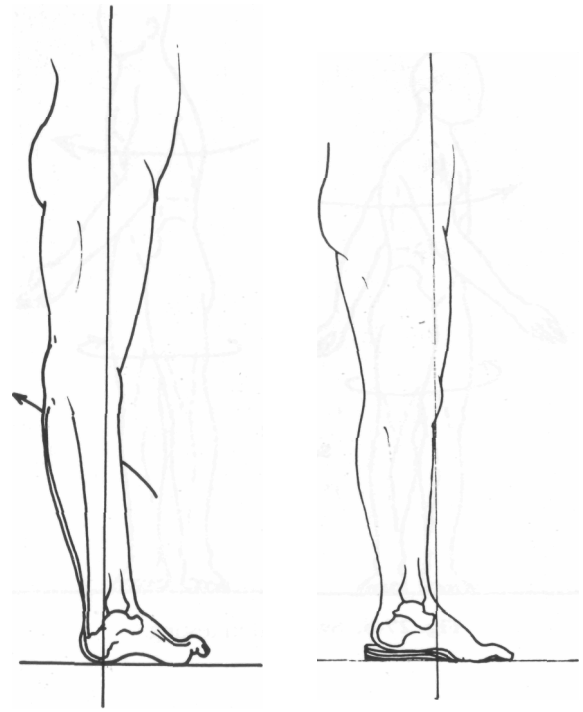

Fig. 27-10. Relaxation of digits through block balancing.

STRUCTURAL ORTHODIGITAL EVALUATION

Radiographic Digital Assessment

Radiographs should be considered an integral part of the orthodigital assessment to help gain an overall understanding of the presented digital problem. In the evaluation, the digital deformities should be straightened with assistive measures, if necessary, before obtaining the radiographs to detect the presence of structural digital anomalies and to help ascertain the nature, location, and extent of deformity (Fig. 27-11). Care must be taken not to overexpose the radiograph as this will obscure distal forefoot detail and hinder an essential portion of the digital evaluation (Fig. 27-12).

Digital Line Up Technique

Although the manual reduction of a digital deformity may indicate a functional developmental influence, the examiner should be careful not to overlook an underlying structural anomaly that may be hidden. To determine if a structural component is present we use the digital line-up technique[2] to uncover masked digital deformities (Fig. 27-13). It is not uncommon for long digits secondary to hyperphalangism to attain an apparently normal digital length pattern by retreating to the common line of gripping. To detect the presence of these camouflaged digits the examiner must straighten all the toes, preferably with the patient standing, noting any irregularities in size, shape, length, and contour as they relate to each other, the hallux, and the normal digital parabola. While these structural deformities are obviously best suited to surgical intervention, the operative approach will cer-

Fig. 27-11. Radiographic digital assessment.

tainly be influenced by the discovery of hidden digital deformities. The surgical implications are extremely important, because the long digit, which may present as a hammer toe deformity, will require an osseous modification procedure rather than a soft tissue procedure (i.e., tenotomy) even though it may have a low taxicity resistance grading (Fig. 27-14).

Acquired Digital Deformity

Positional deformities of a long-standing nature will tend to become chronically adapted at the affected joint of deformation. These adaptive arthropathic changes are not conducive to conservative corrective measures and will usually require invasive operative procedures to restore a more normal digital alignment. Digital deformities that have attained a nontaxic state must now be relegated to the same status as the structural or congenital digital anomaly and should be treated in the same fashion.

Fig. 27-12. Radiographic overexposure hindering digital evaluation.

THERAPEUTIC DIGITAL MANAGEMENT

Relief and Preliminary Care Phase

Once the digital malalignment or deformity has been recognized and classified, the preventive, corrective, and retentive steps of orthodigital therapy can be

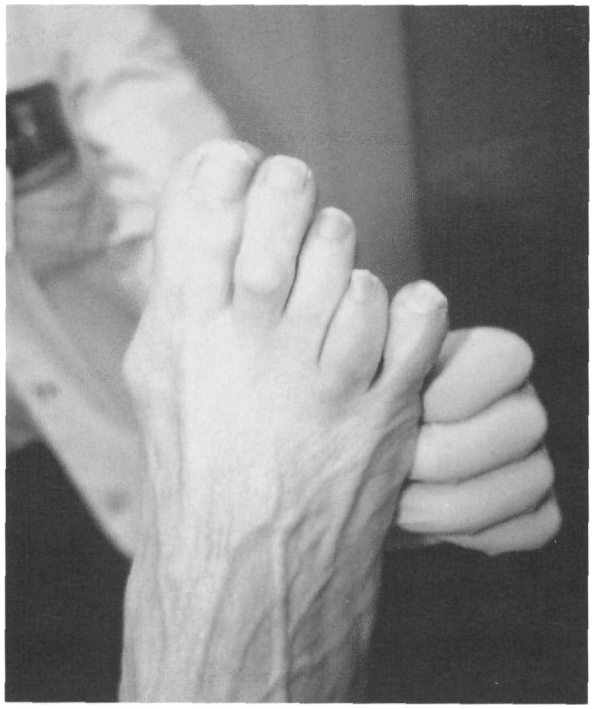

Fig. 27-13. Digital line-up technique.

addressed. Following the initial lower extremity and orthodigital evaluation the patient will generally require and desire some type of immediate attention for the presented digital complaints. Initial treatment may include lesional reduction, protective shielding, trial splinting, and test realignment and rebalance with selected functional foot balance pads.

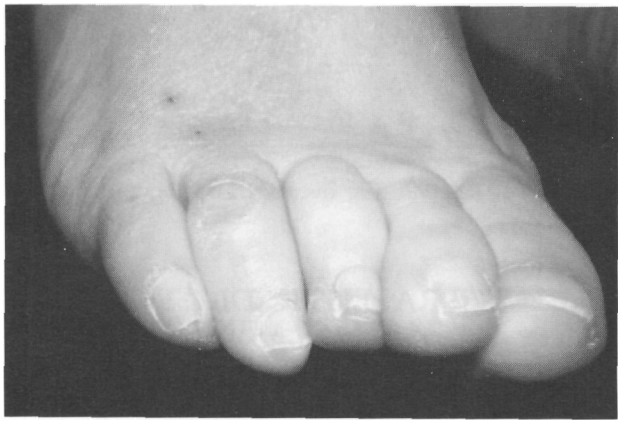

Fig. 27-14. Long fourth digit revealed through a poorly advised tenotomy procedure.

Following lesional debridement, the deformity should be protected against further shoe irritation via precise digital shielding. The skin should be cleansed and prepped with an adherent before padding to provide better contact and, most importantly, to help prevent irritation, maceration, or fungal infection. Sound principles of digital pad design and application should be followed when optimal protective padding qualities are desired. The padding material should be firm enough to shield the lesion or prominence from the offending shoe pressures while not being so firm as to create new direct pad irritations. For this reason the selection of felt materials is generally preferred over softer compressible foam rubber materials.

The size and shape of the pad should be commensurate with the protective need for which it is intended (Fig. 27-15). All pad edges should be beveled and any sharp or abrupt corners are to be avoided to prevent potential irritation. The thickness of the pad is extremely important in that a pad which is either too soft or too shallow will not adequately protect or shield the prominence for which it was designed. A common misconception is that the aperture that is designed to subtract focal pressure should be exactly the same size as the prominence or lesion to be protected. While it is true that an aperture that is too remote will fail to protect, the aperture which is too small may cause irritation of the sensitive area surrounding the lesion. Along these same lines, it is also important to bevel the inner walls of the aperture to prevent excessive edge pressure and irritation (Fig. 27-16).

The first step to achieving long-term success in the management of functionally induced digital deformity is through the recognition and control of the underlying imbalance responsible for the development of the deformity. Toward this goal, the use of functional in-shoe temporary test padding may reduce or eliminate the necessity of further protective or corrective orthodigital measures (Fig. 27-17). Selection of appropriate test pad elements should improve digital function and alignment as lower extremity and foot imbalances are controlled. This padding system also serves to provide valuable information as to the individual patient response to the proposed correction and thus the need for orthotic control. The versatile and highly specific

Fig. 27-15. (A-F) Selected digital and metatarsal shields. *(Figure continues).*

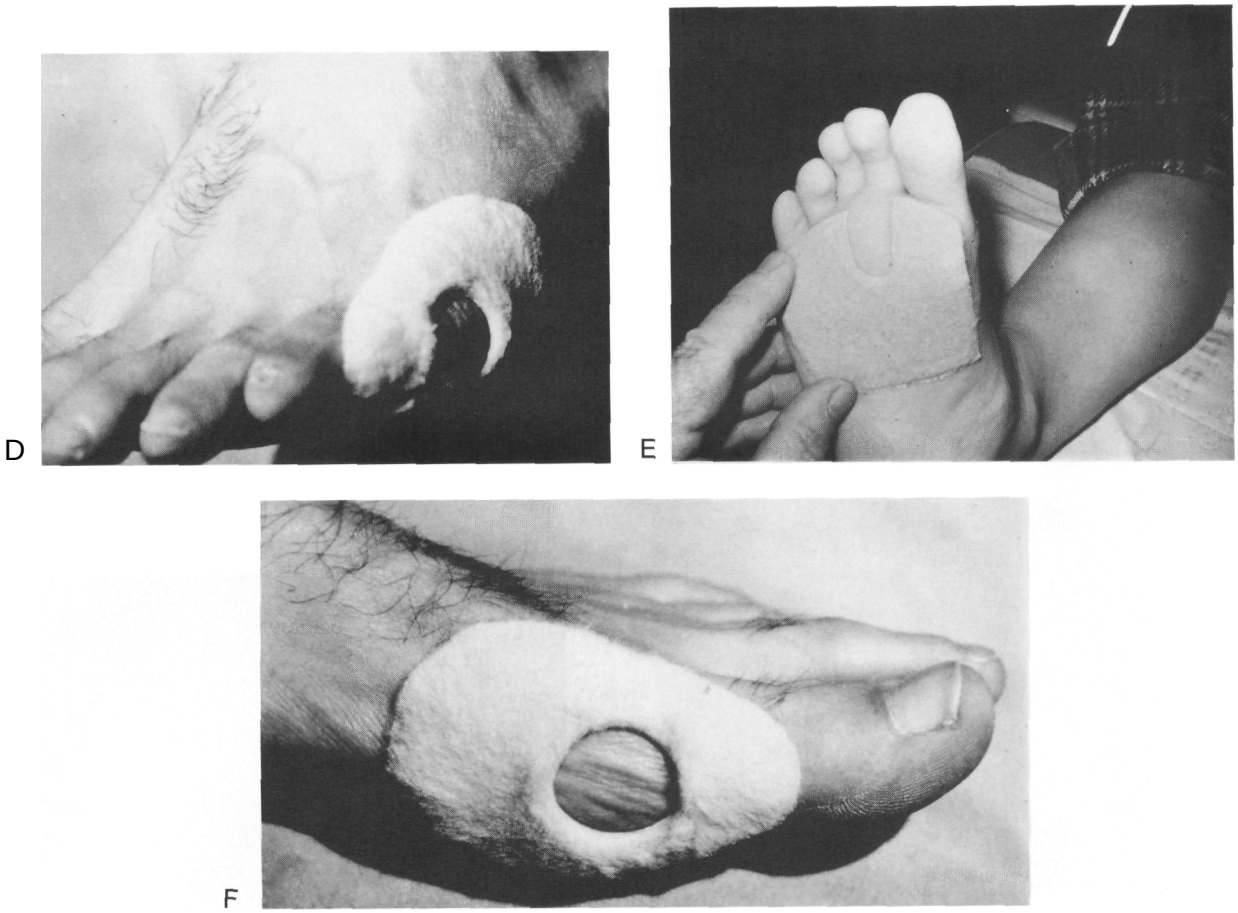

Fig. 27-15 *(Continued).*

nature of the test padding system may be realized with the use of the "varus" test pad to which a Morton's platform or bunion flange may be added as needed (Fig. 27-18).

Additionally, stress reduction through weight management, occupational/avocational trends, postural habits, and general health also have contributory roles. The greatest factor, however, has to be the role of the patient's foot gear as either beneficial or detrimental with respect to the foot and digital problems.

Foot Gear Survey

A careful survey of both the inner and outer shoe should be considered essential for the determination of proper shoe fit and appropriate alterations as well as education as to future shoe selection. Whenever possible, an attempt should be made to help patients select shoes in accordance with their particular foot type. The shoe taper, last, and width are all important considerations in selecting the appropriate shoe style

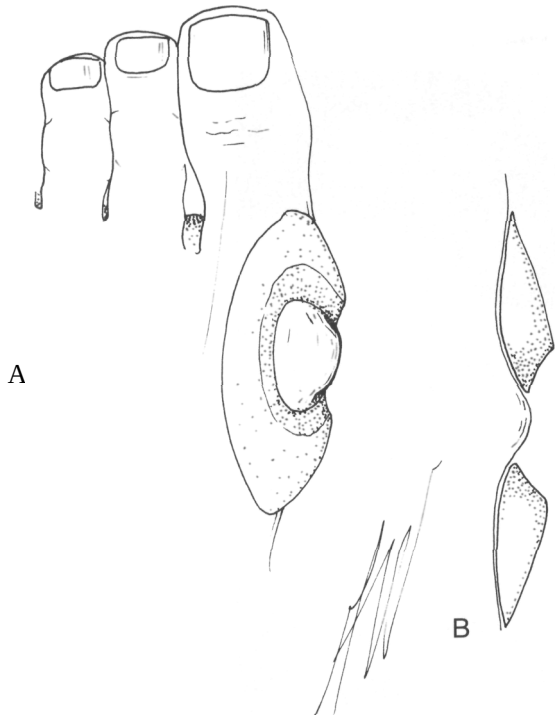

Fig. 27-16. Protective padding of prominences. (A) Full view: (B) profile view.

(Fig. 27-19): I have devised a technique that has proved useful for patient education by demonstrating how existing pressure lesions resulting from shoe-foot conflict can be identified and resolved with a proper shoe selection. An outline of the patient's shoe is traced on transparent acetate film and then placed over a dorsoplantar x-ray projection. This technique is highly graphic in visually demonstrating to the patient the effect of shoe crowding and poor fit on specific anatomic landmarks.

Realignment Phase

Digital deformities that are easily reduced manually will generally respond favorably to conservative orthopedic and orthodigital treatment approaches. Digital malpositions secondary to foot or lower extremity defects must be addressed before any direct digital therapy. Once the underlying imbalance has been resolved through corrective foot bracing and support, any remaining digital malalignment can be effectively addressed. The lower the taxicity resistance grading, the easier the corrective task when coupled with the appropriate orthodigital therapy. Orthodigital techniques such as urethane mold therapy,[4] splinting, tractive therapy,[5] hallux exercise, and other home digital exercise techniques should ensure lasting correction and prevention of recurrence so long as the underlying deforming forces are controlled.

The urethane mold orthosis (UMO) technique as described by Whitney is an extremely versatile orthodigital technique that can be effectively utilized for both corrective and retentive digital alignment needs as well as for protective and prosthetic applications. The UMO device is easily fashioned from blocks of polyurethane foam, being cut to the desired shape with a skiving knife and cork boring punches. Once the device has been properly fitted over the patient's toes, a water-based latex (vultex) is mixed with the foam until it is saturated. The activated mold is then placed back on the foot and covered with a plastic bag; the patient is instructed to wear the device for several hours until the urethane mold orthosis becomes functionally molded within the shoe confines (Fig. (27-20).

Digital traction therapy is another orthodigital technique that has proved extremely useful over the years as a rehabilitative measure for overcoming joint stiffness and adaptive changes secondary to positional imbalance. The original tractive device described and utilized by Budin some 50 years ago has since been refined by Whitney into a lightweight, simple, chairside technique (Fig. 27-21). With a series of office visits the patient may expect to gradually reduce the extent of digital deformity or help to restore motion lost through injury and functional disuse.

A digital band splint may be used for isolated digital deformities that are manually reducible but which still require external assistance to help overcome postural, congenital, or postsurgical malpositional influences (Fig. 27-22).

Motivated and enlightened patients may wish to take an active role in their treatment plan to help ensure success in the shortest possible time. Home exercises, which may include making toe fists, picking up marbles with the toes, and single foot balancing will often help the patient gain the flexibility and strength to

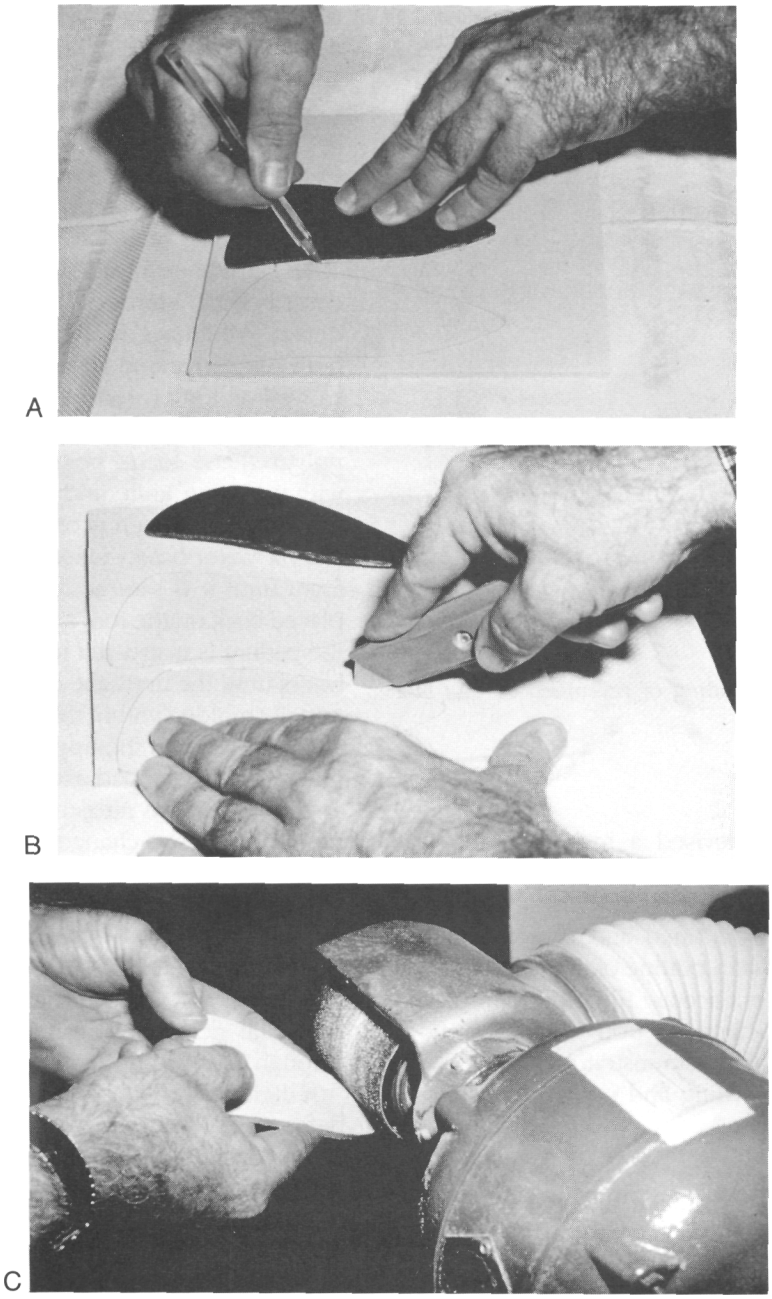

Fig. 27-17. In-shoe temporary test pad technique. (A) Tracing pad design; (B) cutting out pad; (C) bevel grinding pad edges. *(Figure continues.)*

D

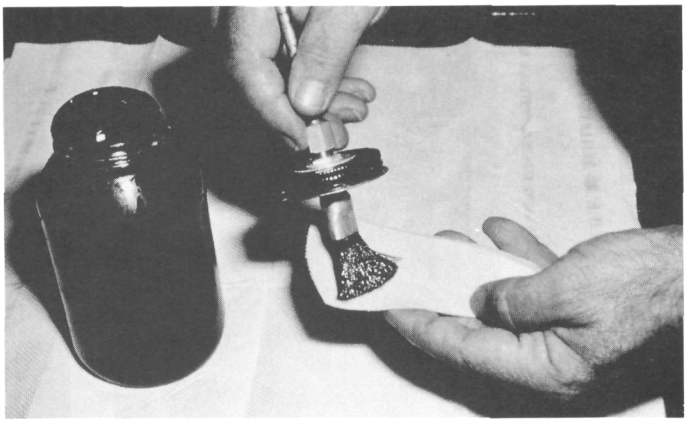

E

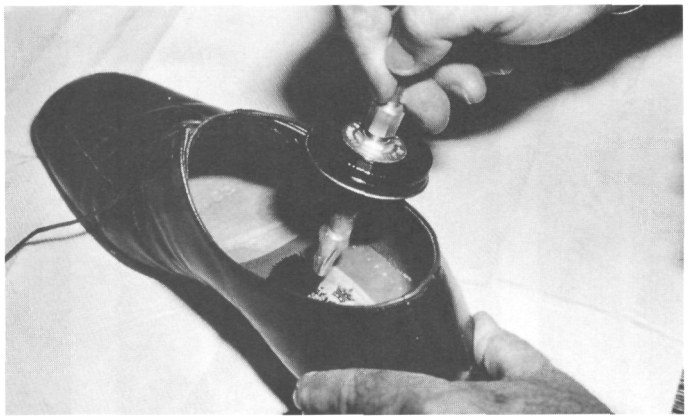

F

Fig. 27-17 *(Continued)*. (D) Rubber cement application to pad; (E) cement application to shoe; (F) pad placement in shoe.

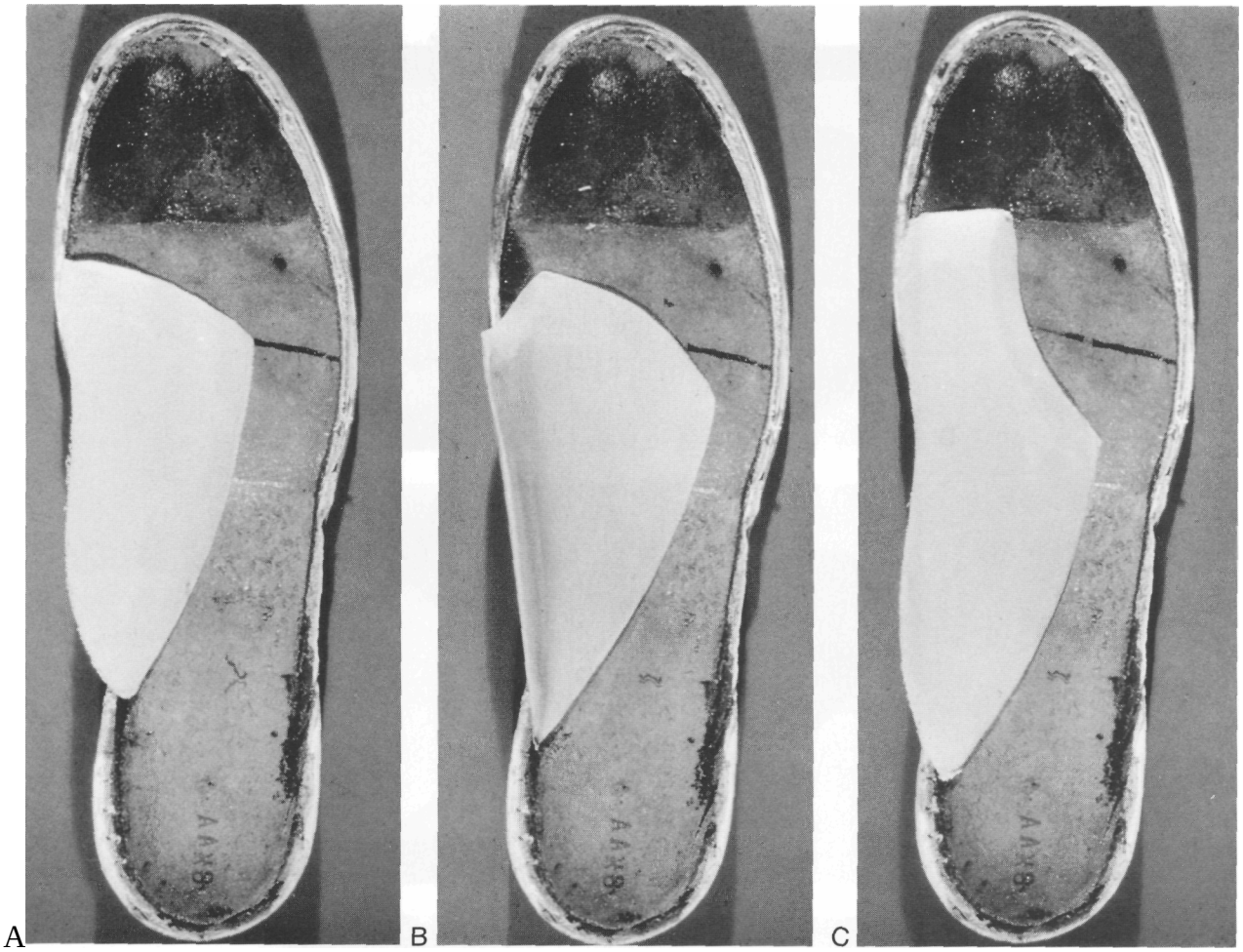

Fig. 27-18. The varus test pad and modifying elements. (A) Varus pad; (B) varus bunion flange pad; (C) varus Morton's extension pad.

overcome digital malpositions more quickly. One such exercise device designed for home use is the "Hallexorcist," which can dramatically reduce the realignment phase of the hallux abductus deformity especially when coupled with retentive and night splint therapy (Fig. 27-23).

Repair Phase

Surgical intervention for structural or chronically adapted digits of a nontaxic nature will generally require a combination of soft tissue release and osseous procedures to render successful realignment and symptomatic relief. Digital deformities with a taxicity resistance grading between 3 and 4, yielding moderate to severe resistance to manual reduction, will usually require tenotomy and capsulotomy procedures in conjunction with conservative orthodigital techniques. Digital deformities that are completely nontaxic or which are only partially reduced with pain (grade 4-5) will require a combination of soft tissue and osseous reconstruction procedures.

Another therapeutic consideration involves the use of conservative protective or accommodative mea-

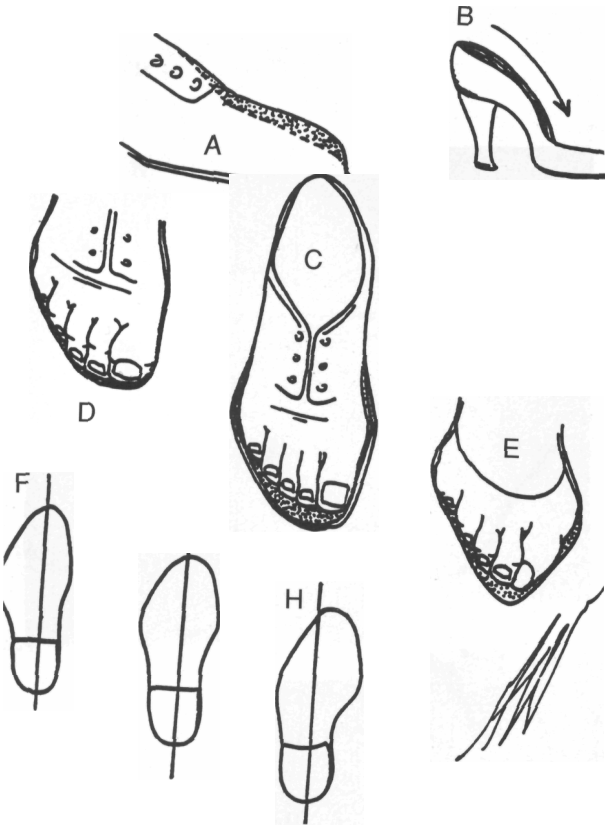

Fig. 27-19. (A—H) Shoe influences and considerations.

sures, which may be preferred when the digital deformity is so advanced that improved digital function will not be achieved through surgical intervention (Fig. 27-24).

Hallux Abducto Valgus Management

Evaluation and treatment of the hallux abducto valgus (HAV) deformity based on the pattern, degree, and taxicity testing offers an enlightening overview of the therapeutic approach to be selected.

The mild or incipient HAV deformity that is minimally deviated with an HAV angle of 15° to 25°) and which is easily reducible with a taxicity resistance grading of 2 or less may be treated conservatively. The use of a dry urethane mold hallux ram crest or silicone spacer is often effective in maintaining the desired hallux position, together with a hallux retention strap and metatarsal elastic binder. The etiologic and aggravating factors must be identified and negated with orthosis application and optimal shoe selection. The use of a hallux night splint (Fig. 27-25) and home digital exercises will also help to hasten the correction process.

Treatment of the moderate HAV deformity demonstrating a malalignment angle of 25° to 35°, mild subluxation, and a taxicity resistance grading between 2 and 4 will generally require a combined orthodigital and surgical approach to effectively treat and correct the problem. Preliminary foot and shoe control must first be achieved with appropriate foot rebalancing and shoe selection. Depending on the relative resistance to manual realignment, a decision involving aggressive digital traction therapy versus selective soft tissue procedures, which may include adductor release-capsulotomy and or a medial capsulorraphy, is determined. The use of a urethane mold ram crest and night splints will help to attain and maintain correction.[6]

Advanced to severe HAV malalignments of 35° or greater with a nonreducible dislocated first metatarsophalangeal joint (Fig. 27-26C) will usually require soft tissue and osseous reconstructive techniques, followed by orthosis control and retentive orthodigital measures to help maintain the correction and to prevent future recurrence. Severely dislocated and rigidly fixed HAV deformities may be best treated with protective orthodigital measures rather than radical surgical intervention. As a general rule, when operative procedures cannot improve digital function, conservative treatment including accommodative shoe presciption, urethane mold shielding, and surgical removal of symptomatic prominences is the preferred approach.

Case Control and Evaluation

The periodic inspection and evaluation of the digital correction and treatment is essential to ensure continued success and maintenance of digital function and correction. Follow-up radiographic studies, models, and photos are extremely useful as reference documents for treatment progress. Foot orthoses should be adjusted or replaced if recurrence of deformity or loss

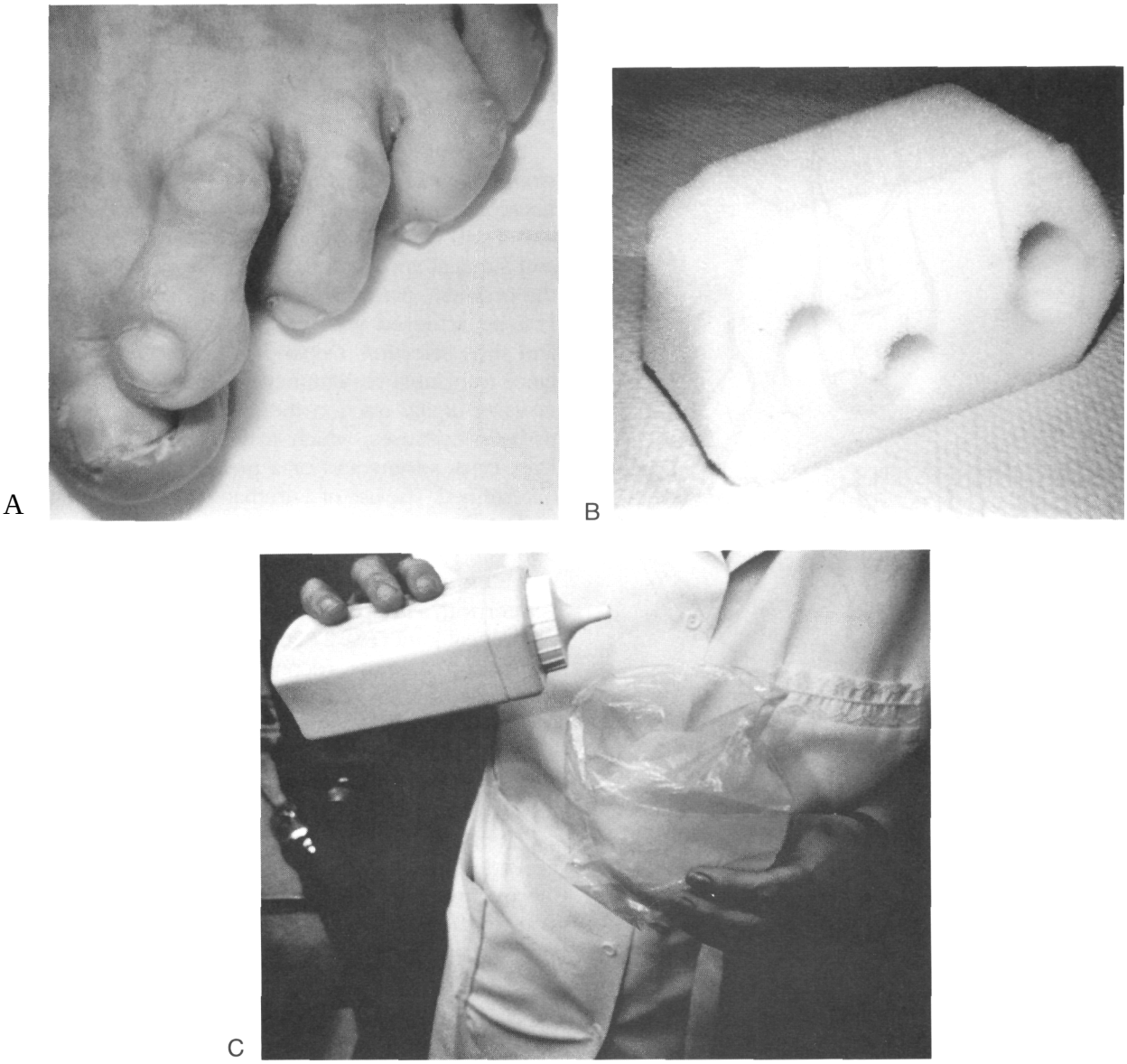

Fig. 27-20. Urethane mold orthosis technique. (A) Digital deformity to be corrected; (B) apertured foam block; (C) adding vultex solution to dry foam. *(Figure continues.)*

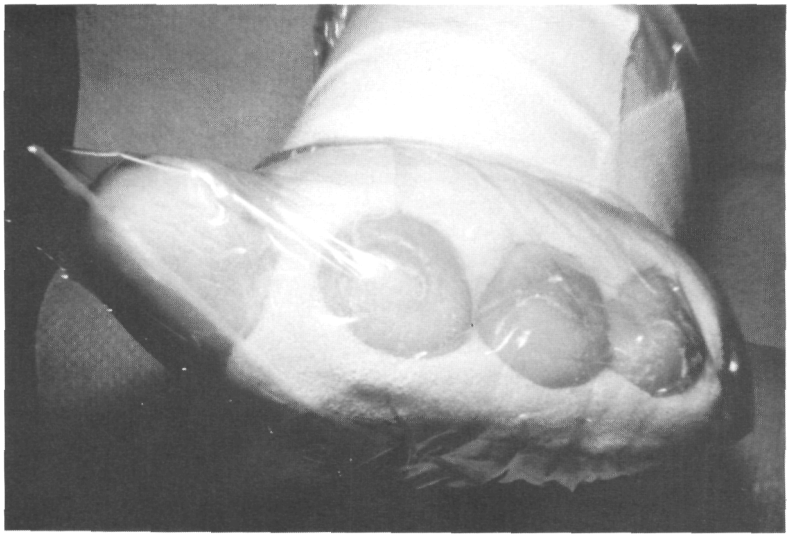

D

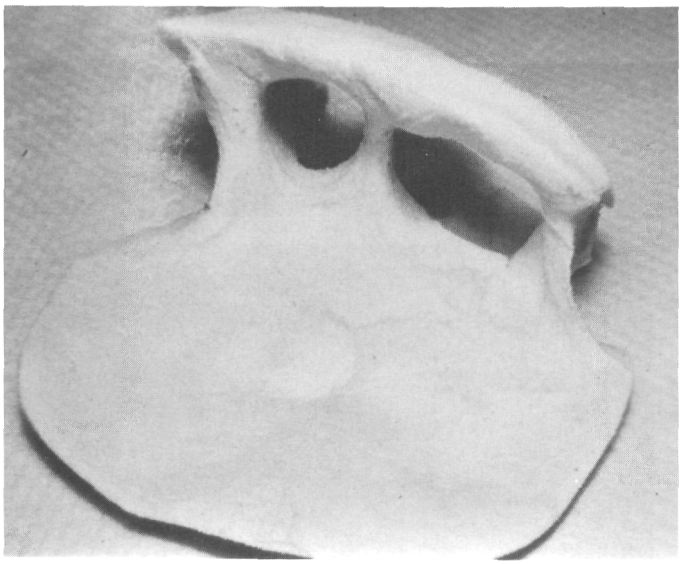

E

Fig. 27-20 *(Continued).* (D) Saturated mold in place over toes; (E) completed urethane mold.

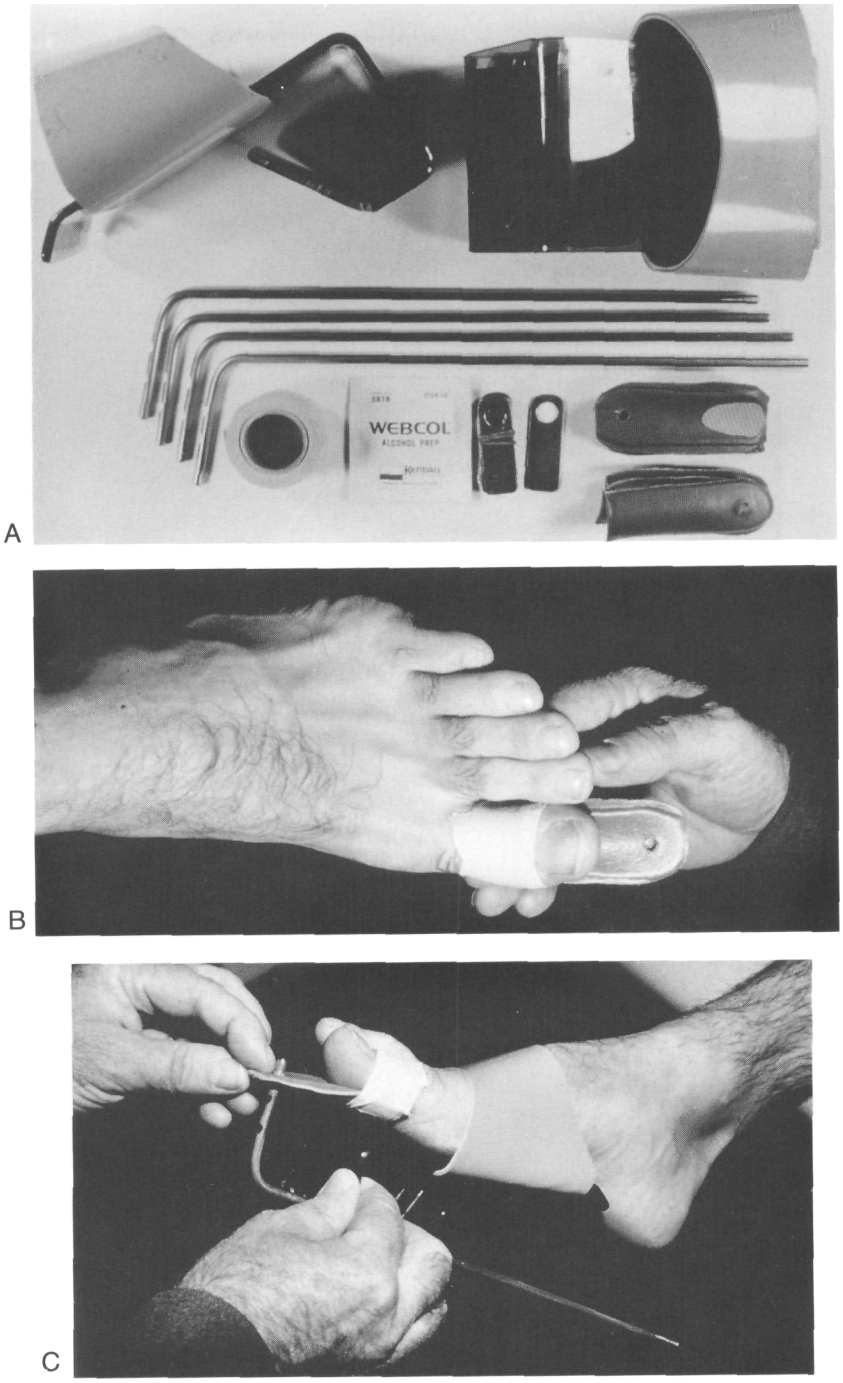

Fig. 27-21. Digital traction technique. (A) Traction device; (B) traction splint taped to hallux; (C) applying tractive force to first MPJ.

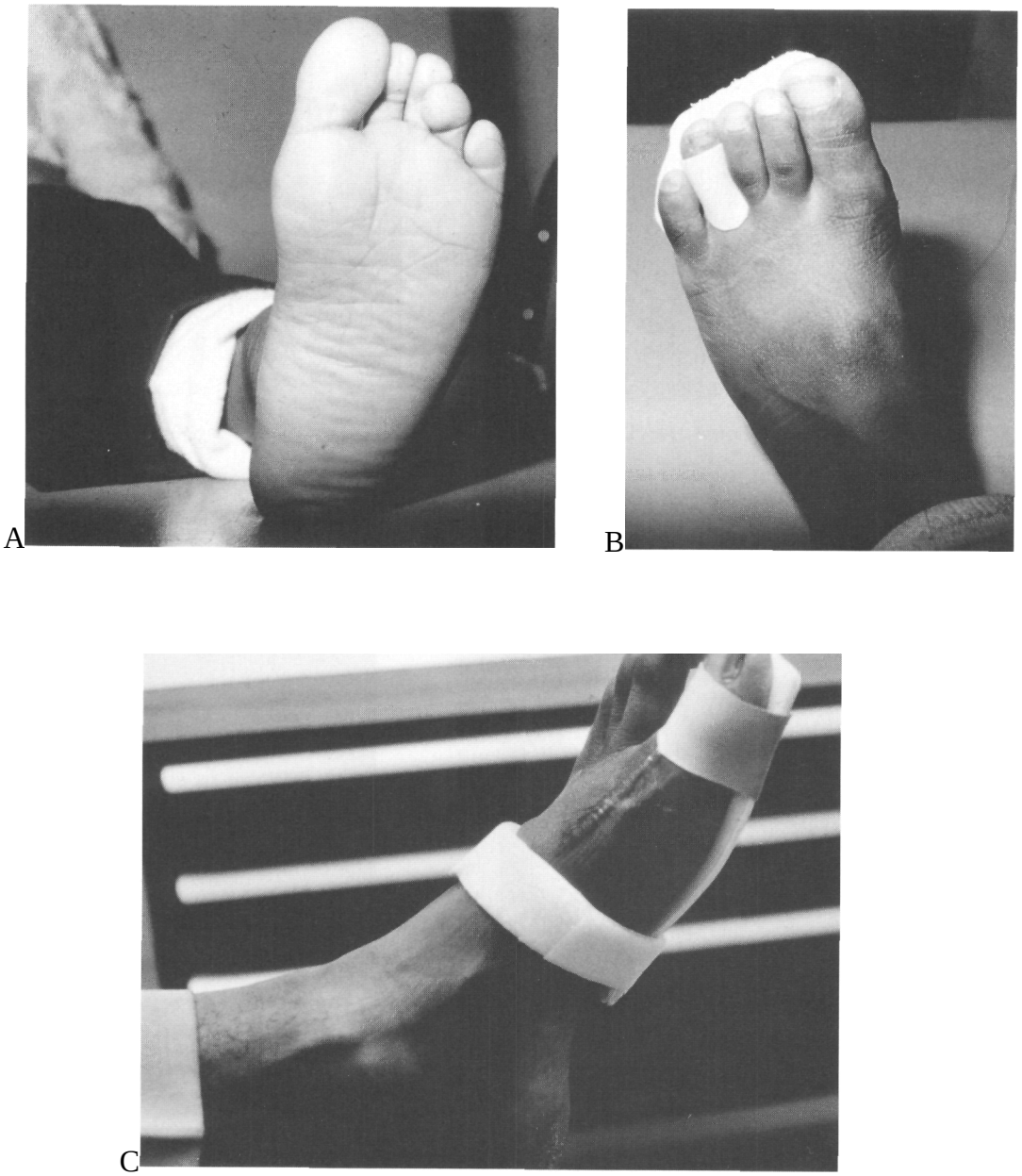

Fig. 27-22. Digital band splint technique. (A) Underlapping fourth toe; (B) realigned toe with splint; (C) post-surgical splint for hallux extensus.

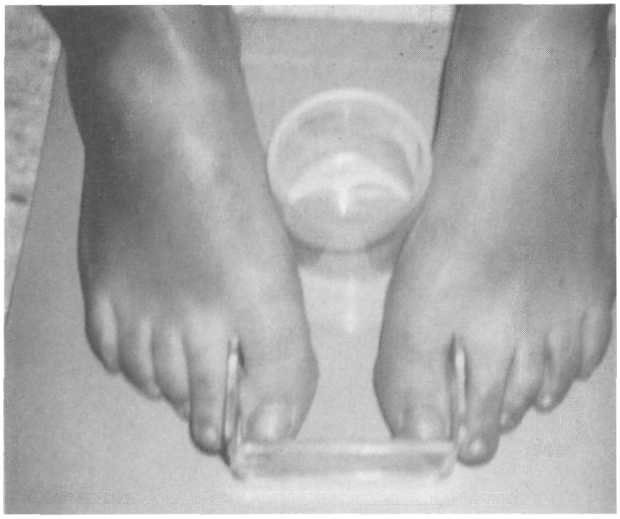

Fig. 27-23. The Hallexercist hallux home exercise device.

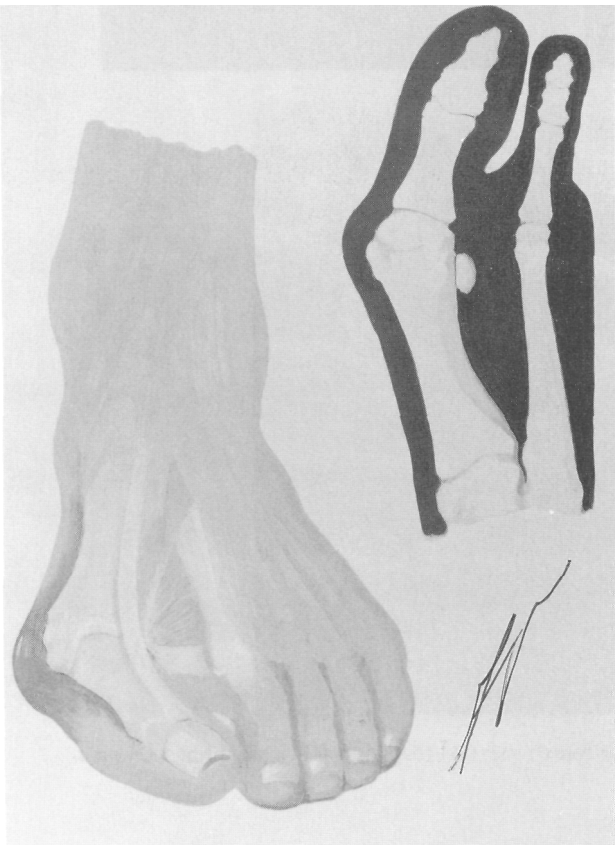

Fig. 27-24. Hallux abducto valgus deformity.

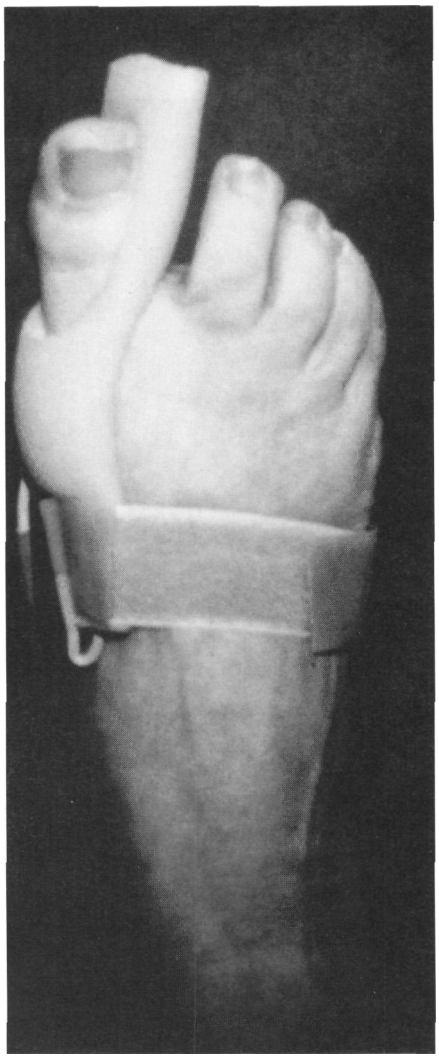

Fig. 27-25. Wire-foam hallux night splint.

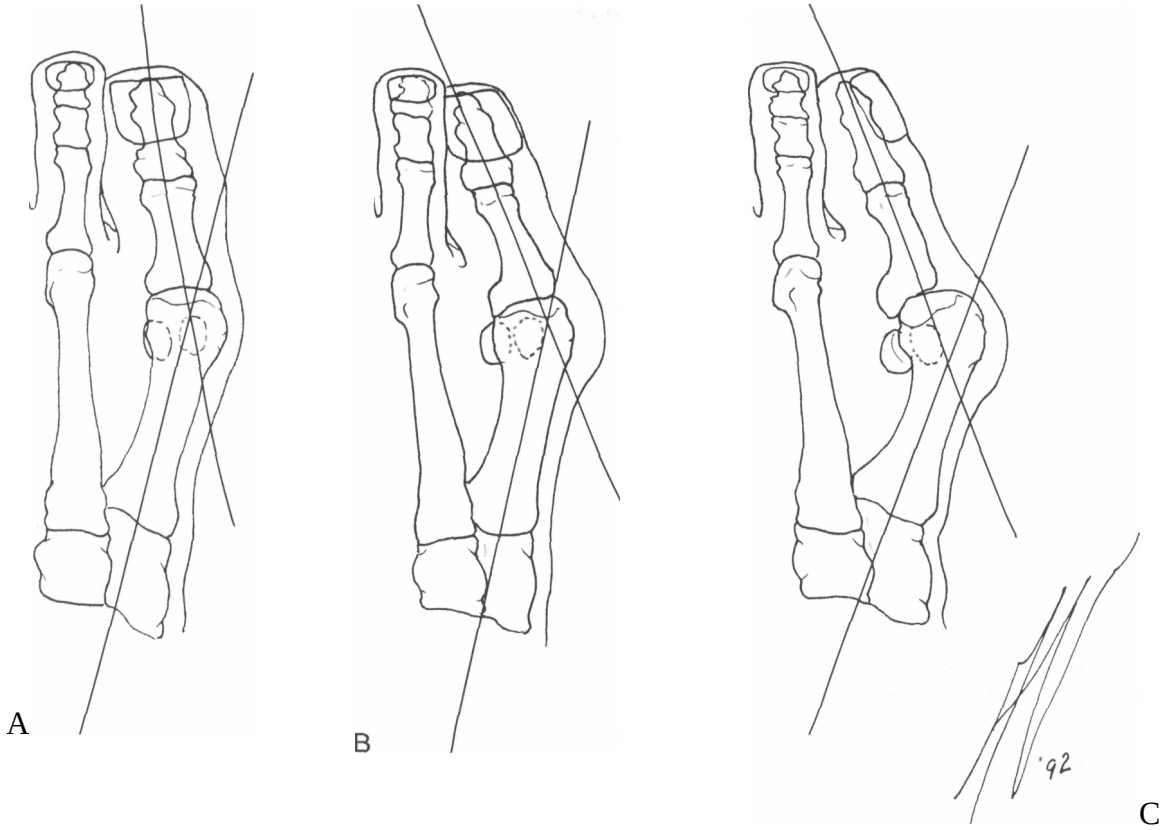

Fig. 27-26. (A) Mild HAV deformity; (B) moderate HAV deformity: (C) advanced to severe HAV deformity.

of digital function is noted. Any digital retainers being used should be inspected and replaced as necessary. The patient's current foot gear should be inspected and discussed with regard to any alterations in style, fit, and heel elevation. Digital stretching or strengthening exercises if still beneficial should also be prescribed or reviewed with the patient.

CONCLUSION

Therapeutic shortcuts may produce disastrous results, but a thorough orthodigital evaluation leading to the most appropriate treatment should ensure gratifying results. Perhaps the most important assurance of long-term success is the patient's comprehension of the proposed treatment program. Through understanding, sustained patient motivation and cooperation are ensured.

REFERENCES

1. Whitney AK: OrthoPodiatric Examination Procedure. Pennsylvania College of Podiatric Medicine, Philadelphia, 1973
2. Whitney KA, Whitney AK: Orthodigita Techniques, Principles and Practice of Podiatric Medicine. Churchill Livingstone, New York, 1990
3. Whitney AK: Biomechanical Footwear Balancing. Pennsylvania College of Podiatric Medicine, Philadelphia, 1979
4. Whitney AK: Urethane mould therapy. N Engl J Podiatry 42:17, 1963
5. Budin HA: Principles and Practice of Orthodigita. Strathmore Press, New York, 1941
6. McGlamery ED: Postoperative use of urethane moulds. J Am Podiatry Assoc 58:169, 1968